

Original papers

A case of *Dipylidium caninum* infection in a child from the southeastern Poland

Bogusława Szwaja, Leszek Romański, Michał Ząbczyk

Laboratory of Parasitology of the District Sanitary and Epidemiological Center, 76 Prądnicka Street, 31-202 Cracow, Poland

Corresponding author: Michał Ząbczyk; E-mail: michalzabczyk@op.pl

ABSTRACT. *Dipylidium caninum* is a common intestinal tapeworm of dogs, cats and foxes. However, it occasionally infects also humans. We present a case of *D. caninum* infection in a 2-year-old child living in the Subcarpathian province. The infection was asymptomatic in the first months. The symptoms of abdominal pains, sleep disorders, loss of appetite, hyperactivity and occasional slimy stools appeared later. Proglottids on the underwear, in water while bathing and mobile proglottids passed with the stool were also observed. Prior to appropriate diagnosis the child was treated with pyrantelium (Pyrantelium) and albendazolum (Zentel). However, proglottids were found again in the stool after a few days. We examined stool samples and perianal smears collected from the child and his family. The stool samples were tested by coproscopic methods. Direct methods (direct preparation in 0.9% sodium chloride and in Lugol's solution, Kato thick smear) and concentration methods (decantation with distilled water and Faust's zinc sulphate centrifugal flotation) were used. In the stool samples taken from the child, we observed *D. caninum* proglottids demonstrating lateral genital pores and many packets of eggs containing from one to a few, mostly 3 to 4 eggs. In the direct preparations in 0.9% sodium chloride and in Lugol's solution single packets with *D. caninum* eggs were detected. In decantation preparations many *D. caninum* egg packets were observed. It has to be reported that the child's mother was infected with *Giardia intestinalis*. Dipylidiasis in humans is a rarely encountered infection in Poland and the diagnosis may be difficult. For these reasons we reported clinical case presentation, diagnostics, treatment and epidemiology of *D. caninum* infection. We have shown that concentration methods such as decantation might be very helpful in the diagnosis of dipylidiasis.

Key words: dipylidiasis, *Dipylidium caninum*, dog tapeworm, zoonoses, Poland

Introduction

Dipylidiasis is an infection caused by *Dipylidium caninum*. *D. caninum* is a common intestinal tapeworm of dogs, cats and foxes. However, it occasionally infects also humans, predominantly children. The intermediate hosts are larval fleas (*Ctenocephalides canis*, *Ctenocephalides felis*, *Pulex irritans*) or a dog's louse (*Trichodectes canis*) [1]. A definitive host can be infected by occasional ingestion of infected insects [1]. A flea may contain multiple tapeworm larvae and in such cases an infection with many tapeworms is possible [2]. Young children are especially exposed to the *D. caninum* infection due to the lack of upheld

cleanliness and personal hygiene rules.

The larvae grow in the small intestine and within 2–3 weeks they mature to an adult form with 15–70 cm long and 2–3 mm thick body [3]. The body is composed of a scolex with four suckers, a neck, and 60 to 175 proglottids [1,3]. The proglottids have 2 lateral genital pores and may be immature, mature or gravid [1]. In gravid proglottids, there occur packets containing from 3 to 30 eggs, mostly 8 to 15 with a diameter of 25–40 µm [1,3,4]. Gravid proglottids look like pumpkin or cucumber seeds and have active movement ability, therefore they can migrate out of the anus or are passed in the stool, which causes the spread of egg packets over dog fur, skin, and in environment [1,2].

Samples of the stool collected from the 33-month-old child in the Subcarpathian province were submitted to the Laboratory of Parasitology of the District Sanitary and Epidemiological Center in Cracow, Poland. For the preceding 4 months the parasite infection was observed in the child. White „worms” bodies were seen on the underwear, in water while bathing, and in the stool. The infection was asymptomatic in the first months and later associated with abdominal pain, sleep disorders, loss of appetite, hyperactivity and occasional slimy stools. After 2 months from the first symptoms, the child was treated with pyrantelium (Pyrantelium) and albendazolum (Zentel). Although the family members did not observe any disorders, albendazolum treatment was administered to all the family, except the pregnant mother of the infected child. After a few days from the onset of the therapy, mobile „worms” bodies were still observed in the stool of the child. The local microbiological laboratory in the home town did not identify the parasite species and further diagnostics in a specialist laboratory was proposed. Moreover, there were no pathological changes in the blood and urine samples. Eosinophil count was from 0.8% (automatic method) to 2% (manual blood smear). Erythrocytes sedimentation rate (ESR) after one hour was 6 mm. The family has domesticated dogs and cats. The child, however, had also contact with stray cats.

The aim of this study was a case description of *D. caninum* infection in the 33-month-old child.

Materials and methods

Samples (proglottids, stool, perianal smear) taken from the child, his parents, and grandparents living together in the family house were examined macro- and microscopically (microscope ECLIPSE E 400, Nikon, Japan). Stool samples were tested with the use of coproscopic methods. Direct methods (direct preparation in 0.9% sodium chloride and in Lugol’s solution, Kato thick smear) and concentration methods (decantation with distilled water and Faust’s zinc sulphate centrifugal flotation) were used [1,5]. Preparations after concentration methods were done in Lugol’s solution. Perianal smears were examined using the National Institute of Health of the U.S. Public Health Institute (NIH) swab method [6]. Slides were examined at $\times 100$ and 400 magnification. Microscopic photo images were done with an

inverted microscope (Axiovert S100, Zeiss, Germany) with a digital camera. In the case of *Giardia intestinalis* diagnosis, additionally ELISA immunoassay for the coproantigen GSA-65 *G. intestinalis* RIDASCREEN Giardia (R-Biopharm, Germany) was used.

Results

In two stool samples collected from the child, *D. caninum* proglottids demonstrating lateral genital pores were observed (Fig. 1). The proglottids were 10–15 mm long and 2–3 mm thick. Microscopic




Fig. 1. *Dipylidium caninum* proglottid demonstrating genital pores. Scale bar =1cm.

examination of proglottids showed characteristic brown packets with *D. caninum* eggs. There were a dozen or more packets in each proglottid containing from one to a few, mostly 3–4 eggs. In direct preparations in 0.9% sodium chloride and in Lugol’s solution, single packets with *D. caninum* eggs were found. The decantation technique, revealed many *D. caninum* egg packets (Fig. 2). The eggs contained round oncospheres with thick embryonic membranes around them. Preparations

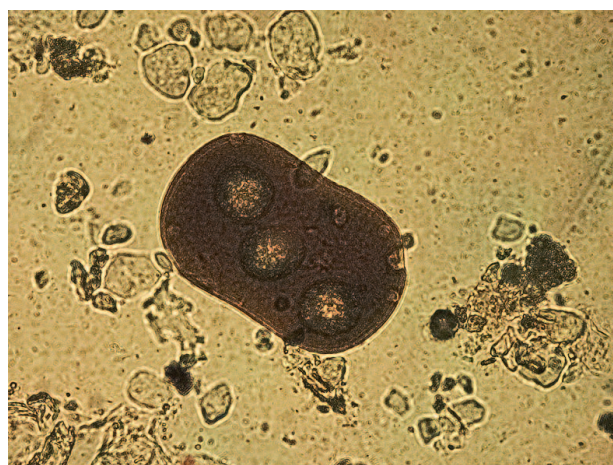

Fig. 2. Packet of eggs of *Dipylidium caninum*. Magnification $200\times$.

from the remaining methods were parasitologically clean. Both in direct preparations with 0.9% sodium chloride, Lugol's solution and in the decantation and Faust's flotation preparations from the stool samples from the child's mother, the cysts of *G. intestinalis* were found. Additionally, ELISA immunoassay confirmed the presence of coproantigen GSA-65 of *G. intestinalis*. In the remaining family members no intestinal parasites were diagnosed.

Discussion

In the last decade, only a few cases of *D. caninum* human infections from all over the world were reported [2,7,8]. Most infections have predominantly occurred among children and one-third of these cases among infants up to 6 months or younger, especially those in close association with infected dogs and cats [2,9]. In children the infection may be unrecognized or misdiagnosed due to the proglottids in feces going unnoticed and few clinical signs associated with this infection [2]. Human infection with *D. caninum* is usually asymptomatic. In children, however, it can be associated with abdominal pain, indigestion, diarrhea, loss of appetite, irritability, urticaria, and eosinophilia [3,9]. Pathogenicity can be partially related to the absorption of various metabolic wastes of the tapeworm [2].

Dipylidiasis can be incorrectly diagnosed as an *Enterobius vermicularis* infection due to mobile proglottids occurrence around the anus [10]. In one reported case, *Hymenolepis diminuta* infection in child was misdiagnosed as *D. caninum* infection on the basis of proglottids morphology and stool samples examination [11].

Last isolated human infections in Poland were noted in 2000 and 2001 [12,13]. However, the current epidemiological status of dipylidiasis in Poland is unknown owing to the lack of obligation to inform epidemiological supervision about intestinal tapeworm infections (Journal of Laws of the Republic of Poland 2008, No. 234, item 1570).

Accurate diagnosis of *D. caninum* depends on detection of proglottids wandering out of the anus or proglottids and/or typical egg packets in stool. In the preparations of proglottids, pathognomics for *D. caninum* packets with eggs occurred [2]. Packets of eggs and characteristic double genital pores can be identified by light microscopic examination of proglottids compressed into glass slides [2]. In fresh

stool samples the eggs of *D. caninum* can occasionally be found but they, however, disintegrate rapidly [2].

In present case, in decantation preparations a few packets with eggs of *D. caninum* were found, whose occurrence was directly associated with gravid proglottids in stool specimens. Single egg packets were also detected in direct preparations from stool samples.

In the described preschool child infected with *D. caninum*, praziquantelium (Cesol) in a single dose of 10 mg/kg b.m. was administered. The treatment was effective. Proglottids were observed in stool during the first 3 days after the therapy and then there were no present proglottids and egg packets in stool samples taken from the child in control coproscopic examinations. In addition, household pets were treated with praziquantelium and fenbendazole (Aniprazol), together with an anti-flea medication.

Ładczuk et al. [14] showed that in the area of Szczecin, *D. caninum* was a predominant parasite in the alimentary canal of cats from the Animal Protection Society (18.5%). It occurred less frequently among stray cats (14.2%) and the rarest in domestic cats (1.13%).

Tylkowska et al. [15] showed that *D. caninum* proglottids were, in turn, found in 4.07% of dogs fecal samples from Western Pomerania.

Prophylaxis of dipylidiasis is based on upholding cleanliness, personal hygiene, and both the limitation of the spread of *D. caninum* eggs in the environment as well as protection of children in places in which dogs or cats are present.

In humans, *D. caninum* infections are relatively rare and particularly affect preschool children. Nevertheless, the description of human cases with *D. caninum* infections can be necessary from the epidemiological and clinical viewpoint. Our study showed that concentration methods such as decantation might be very helpful in diagnosis of dipylidiasis.

References

- [1] R. Kadłubowski, A. Kurnatowska. 1999. Zarys parazytologii lekarskiej. Wydawnictwo Lekarskie PZWL, Warszawa.
- [2] Molina C.P., Ogburn J., Adegboyega P. 2003. Infection by *Dipylidium caninum* in an infant. *Archives of Pathology and Laboratory Medicine* 127: 157-159.
- [3] Buczek A. 2005. Choroby pasożytnicze. Epidemiologia, diagnostyka, objawy. Koliber, Lublin.

- [4] Buczek A. 2005. Atlas pasożytów człowieka. Koliber, Lublin.
- [5] Nowak P., Jochymek M., Pietrzyk A. 2007. Occurrence of human intestinal parasites in selected populations of Cracow region in the years 2000–2006 on the basis of parasitological stool examinations performed in the Laboratory of Parasitology of the District Sanitary-Epidemiological Center. *Wiadomości Parazytologiczne* 53: 285-293.
- [6] Watson J.M., Mackeith R. 1952. The comparative efficiency of various techniques for the diagnosis of threadworm infection. *Archives of Disease in Childhood* 27: 526-532.
- [7] Neira O.P., Jofré M.L., Muñoz S.N. 2008. *Dipylidium caninum* infection in a 2-year-old infant: case report and literature review. *Revista Chilena de Infectología: órgano oficial de la Sociedad Chilena de Infectología* 25: 465-471.
- [8] Tsumura N., Koga H., Hidaka H., Mukai F., Ikenaga M., Otsu Y., Masunaga K., Nagai K., Yoneda Y., Fukuma T., Ishimoto K. 2007. *Dipylidium caninum* infection in an infant. *Kansenshōgaku Zasshi. The Journal of the Japanese Association for Infectious Diseases* 81: 456-458.
- [9] Neafie R.C., Marty A.M. 1993. Unusual infections in humans. *Clinical Microbiology Reviews* 6: 34-56.
- [10] Samkari A., Kiska D.L., Riddell S.W., Wilson K., Weiner L.B., Domachowske J.B. 2008. *Dipylidium caninum* mimicking recurrent *Enterobius vermicularis* (pinworm) infection. *Clinical Pediatrics* 47: 397-399.
- [11] Patamia I., Cappello E., Castellano-Chiodo D., Greco F., Nigro L., Cacopardo B. 2010. A human case of *Hymenolepis diminuta* in a child from eastern Sicily. *The Korean Journal of Parasitology* 48: 167-169.
- [12] Płonka W., Waloch M. 2002. Cestode infections in Poland in 2000. *Przegląd Epidemiologiczny* 56: 357-361.
- [13] Waloch M. 2003. Cestode infections in Poland in 2001. *Przegląd Epidemiologiczny* 57: 159-163.
- [14] Ładczuk D., Balicka-Ramisz A. 2010. Occurrence of parasites in the alimentary canal of cats from Szczecin area, Poland. *Wiadomości Parazytologiczne* 56: 235-242.
- [15] Tylkowska A., Pilarczyk B., Gregorczyk A., Templin E. 2010. Gastrointestinal helminths of dogs in Western Pomerania, Poland. *Wiadomości Parazytologiczne* 56: 269-276.

Received 20 May 2011

Accepted 28 June 2011