

Case reports

A rare case of primary renal hydatid cyst

Rashi Garg¹, Uma Nahar¹, A.K. Mandal²

¹Department of Histopathology, ²Department of Urology; Postgraduate Institute of Medical Education and Research (P.G.I.M.E.R.), Sector 12, Chandigarh 160017, India

Corresponding author: Rashi Garg; e-mail: rashiigarg@gmail.com

ABSTRACT. Involvement of the kidney is a rare clinical scenario seen in case of *Echinococcus* infection, with isolated involvement of the kidney being even rarer. Patient may be asymptomatic or present with symptoms of lumbar region pain, haematuria, and hydatiduria. We present a rare case of primary right renal hydatid cyst with presenting features of right lumbar pain.

Key words: renal, hydatid cyst

Introduction

Isolated involvement of kidneys is a rare clinical scenario encompassing only 2–3% of cases [1]. Here we are presenting a rare case of renal hydatid cyst, diagnosed on CECT and immunology which was further confirmed on histology after cystectomy was done.

Case history

A 23-years-old female suffered from severe non-radiating pain in her right flank. Pain was not associated with nausea and vomiting. There was no fever. The remainder of the systemic examination was normal. Contrast Enhanced Computed Tomography (CECT) of the upper abdomen showed heterogenous lesion measuring 10.6 cm in diameter in the lower pole of right kidney, which consisted of 3 thin walled cysts of 4.5–5.5 cm each in diameter. CECT was suggestive of a cystic angiomyolipoma/hydatid cyst. Immunological tests were carried out, they revealed elevated *Echinococcus* antibody titers, i.e., *Echinococcus* IgG levels were 2.74 (positive values are >1.1). Other investigations including blood urea and serum creatinine were within normal range. Then open cystectomy was done. Histopathological examination revealed pericyst and ectocyst. Pericyst was composed of

fibrocollagenous tissue with giant cell reaction, proliferating blood vessels and inflammatory infiltrate comprising of lymphocytes and plasma cells. Surrounding renal parenchyma was not seen. Ectocyst was composed of acellular eosinophilic laminated structure (Figs. 1,2).

Discussion

Echinococcosis is world wide zoonosis produced by the larval stage of *E. granulosus*. The adult worm lives in the proximal small intestine of the definitive host and attaches to the mucosa by means of hooklets. Eggs are released into the intestine of the host and excreted in the faeces. Humans become intermediate hosts by contact with definitive host (usually a dog) or ingestion of contaminated soil or water or vegetables. The ovum loses its protective coating on undergoing digestion in the duodenum. Once the parasitic embryo passes through the intestinal wall to reach the portal venous system or the lymphatic system, the liver acts as a first line of the defense and is most commonly involved (75%), followed by involvement of the lungs (15%) which act as the second site of filtration of the hydatid cyst. Haematogenous dissemination may lead to secondary involvement of almost any anatomical location [2]. Involvement of the kidneys is extremely rare (2–3%) [1,3]. Renal hydatid cysts

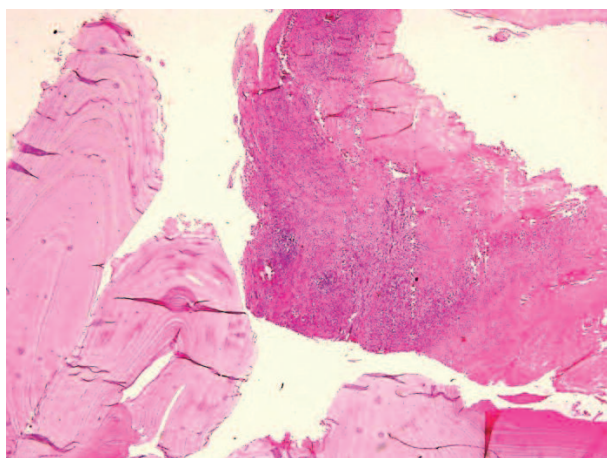


Fig. 1. Microphotograph shows: 1) pericyst composed of fibrocollagenous tissue, proliferating blood vessels and inflammatory infiltrate; 2) ectocyst composed of acellular eosinophilic laminated structures (H&Ex 4×)

usually remain asymptomatic for many years. It is postulated that the cysts pass through the portal system into the liver and retroperitoneal lymphatics to reach the kidneys. The hydatid cyst of the kidney is considered closed if all three layers of the cyst i.e. pericyst, ectocyst and endocyst are intact. When the cyst is no longer protected by the third layer i.e. pericyst or by the lining of collecting system it is considered to be an exposed cyst. If all the three layers of the cyst have ruptured resulting in free communication with the calyces and pelvis [1,4], it is called an open or communicating cyst. Cystic rupture into the collecting system, causing hydatiduria is pathognomonic of renal hydatidosis, though it is usually microscopic and is seen in only 10–20% of renal hydatidosis [5]. Gross hydatiduria is uncommon, but diagnostic of the condition. The cysts passed in the urine are daughter cysts; hence

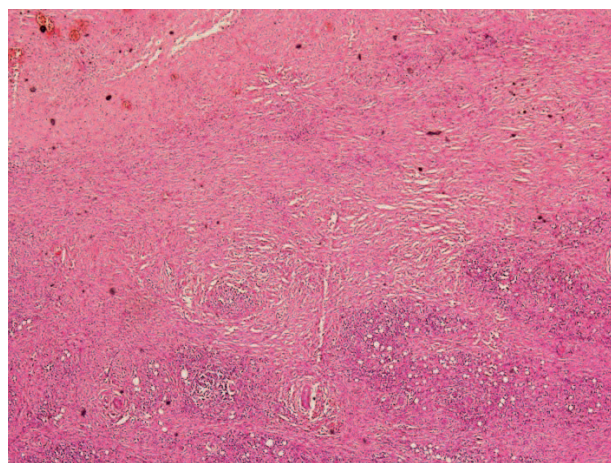


Fig. 2. High power view of pericyst showing giant cell granulomas in fibrocollagenous tissue

they lack the third layer pericyst, which is contributed by the host around the mother cyst. Eosinophilia is noted in about 50% cases. Serological tests in primary renal hydatidosis are usually negative. The mainstay of diagnosis is by advanced radiological techniques like CT scan and magnetic resonance imaging [1,4]. Surgery is the treatment of choice in cases of renal hydatid cyst. Kidney sparing hydatid cyst removal (cystectomy with pericystectomy), is possible in most cases (75%). Nephrectomy (25%) is considered only if the kidney is destroyed by the cyst [6].

Both open and laparoscopic techniques have been described. There is fear of cyst rupture and dissemination during laparoscopy. Utmost care should be taken to prevent spillage and resultant disseminated hydatidosis during the surgery. During kidney-sparing surgery scolicidal solutions such as hypertonic saline should be used before opening the cavities to kill the daughter cysts and therefore prevent further spread or anaphylactic reaction. Pre- and postoperative course of albendazole is recommended to sterilize the cyst, decrease the chance of anaphylaxis and decrease the tension in the cyst wall thus reducing the risk of spillage during surgery and recurrence, post operatively [1,7].

Conclusions

Most cases of renal hydatosis are dealt with open surgery i.e. cystectomy with pericystectomy. In this case also, a kidney sparing cystectomy was done with approximation of the edges of the pericyst over a drain. More studies are needed on such rare cases of primary renal hydatidosis to define a standard treatment modality after comparing the various available options. Also minimally invasive approach needs to be studied in comparison with the open approach.

References

- [1] Mongha R., Narayan S., Kundu A.K. 2008. Primary hydatid cyst of kidney and ureter with gross hydatiduria: a case report and evaluation of radiological features. *Indian Journal of Urology* 24: 116-117.
- [2] Afsar H., Yagci F., Aybasi N., Meto S. 1994. Hydatid disease of the kidney. *British Journal of Urology* 73: 17-22.
- [3] Saxena S., Gupta R., Nigam D.K., Tahiliani N.D.,

- Saxena K.N. 1990. Hydatid cyst of kidney presenting as hydatiduria. *Journal of the Association of Physicians of India* 38: 359-360.
- [4] von Sinner W.N., Hellstrom M., Kagevi I., Norlen B.J. 1993. Hydatid disease of the urinary tract. *Journal of Urology* 149: 577-580.
- [5] Unsal A., Cimentepe E., Dilmen G., Yenidunya S., Saglam R. 2001. An unusual cause of renal colic: Hydatiduria. *International Journal of Urology* 8: 319-321.
- [6] Zmerli S., Ayed M., Horchani A., Chami I., El Ouakdi M, Ben Slama M.R. 2001. Hydatid cyst of the kidney: diagnosis and treatment. *World Journal of Surgery* 25: 68-74.
- [7] Prabhudessai S.C., Patankar R.V., Bradoo A. 2009. Laparoscopic treatment of renal hydatid cyst. *Journal of Minimal Access Surgery* 5: 20-21.

Received 13 April 2015

Accepted 18 May 2015