

Short notes

A new occurrence of *Eimeria catubrina* (Apicomplexa: Eimeridae) in elk (*Alces alces*) from the Kampinos Forest

Katarzyna J. Filip, Aleksander W. Demiaszkiewicz

W. Stefański Institute of Parasitology PAS, Twarda 51/55, 00-818 Warsaw, Poland

Corresponding Author: Katarzyna Filip; e-mail: katarzyna.filip@twarda.pan.pl

ABSTRACT. A three-year-old elk was necropsied in Kampinos Forest, near the village of Granica. An analysis of a 3g faecal sample from the animal revealed the presence of 130 oocysts of *Eimeria catubrina*. The parasite is typical of roe deer; this study is only the second reported observation of *E. catubrina* in elks. As coccidia are so rarely found in elks, this observation of *E. catubrina* in this new localization is a matter of concern.

Key words: *Eimeria catubrina*, *Alces alces*, Kampinos Forest

Introduction

Coccidia from the genus *Eimeria* sp. are single-celled parasites localised in the epithelium of the gastrointestinal tract. Although these parasites are common in most wild ruminants, including roe deer [1], red deer [2] and European bison [3], coccidial infections are rarely observed in elks. The most commonly-observed *Eimeria* species found in elk is *E. alces*, a typical parasite of the elk which has been observed only in Lithuania, Russia, Belarus and Poland. Another species, *E. catubrina*, has been found only once, in an elk from the Białowieża Forest, and is considered to be originally a parasite of roe deer [4].

The aim of this study is to report the discovery of an *E. catubrina* infection in an elk from the Kampinos Forest. Coccidiosis can result in diarrhoea, growth inhibition and even death, especially in young animals [5]. As few studies have examined the elk population of Poland and hunting is uncommon, little is known of their health; in addition, the presence of an unusual infection with coccidia in a new area of the country could constitute a potential threat for the population.

Materials and Methods

In September 2016, a necropsy was performed of a three-year-old male elk in Kampinos Forest, near

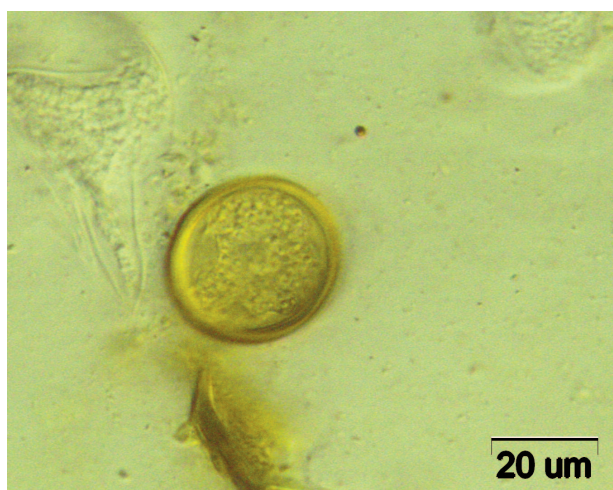
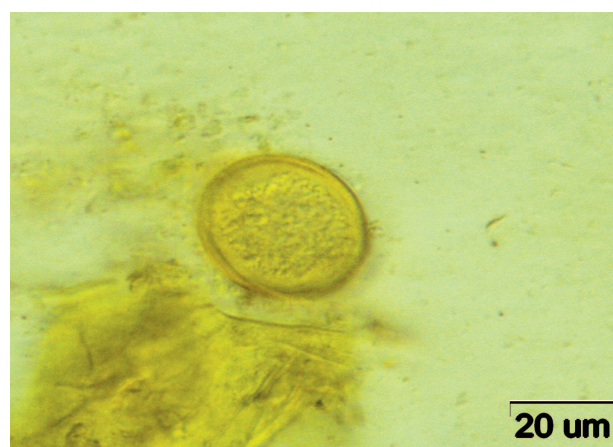


Fig.1-2. Oocysts of *Eimeria catubrina*

the village of Granica. The animal was killed by another male during the mating season. A faecal sample was collected directly from the rectum of the necropsied elk. Under laboratory conditions, three grams of faeces were examined by flotation in sucrose solution, according to Willis [6]. Any oocysts present were measured and counted under the light microscope at x1000 magnification. The oocysts were identified based on morphometrical features [7].

Results and Discussion

The examination of the elk faecal sample revealed the presence of 130 oocysts, belonging to the species *E. catubrina* (Fig.1,2): a parasite typical of roe deer [8]. To our knowledge, this is only the second report of *E. catubrina* infection in elk. The previous sighting was in a single Polish elk from the Białowieża Forest, in which 50 oocysts were found per gram of faeces [4]. The authors suggest that this occurrence in an elk of a species typical of roe deer was an example of parasite exchange between wild ruminants living in the same habitat.

Despite the fact that *E. alces* is considered to be a typical parasite of the elk, its occurrence has only been reported a few times in the world. In the Augustowska Forest, Poland, only one elk from 128 examined animals was found to be infected with *E. alces*, with 100 oocysts identified per gram of faeces [4]. Another report of *E. alces* in Poland came from the Polesie National Park, where four of 114 analysed samples were positive [9]. Interestingly, this infection was the highest reported so far, with the four positive samples containing approximately 9931, 590, 46 and 2994 oocysts in three grams of faeces.

E. alces infections reported in other countries are characterised by significantly lower intensity. In Lithuania, infection was observed in nine of 223 examined animals, and no more than nine or ten oocysts were seen within the field of the microscope [10]. Similar infections were observed by Soshkin in one of six analysed samples from the Zlynkovski District, Russia [11], and by Pen'kevič in 12.2% of examined animals from Belarus [12]. It is important to note that the observation of *E. catubrina* in elks from the Białowieża Forest and from the Kampinos Forest in the present report are the only incidences of elk infection with species of *Eimeria* other than *E. alces*.

Pyziel and Demiaszkiewicz [4] suggest that the

animal from Białowieża Forest was infected as a result of parasite transmission between elks and roe deer. It is possible that watering places common for both ruminants were the source of infection. Similarly, it is an interesting question whether the *E. catubrina* infection in the elk from the Kampinos Forest occurred as a result of parasite exchange. As elks are capable of moving great distances and transmitting parasitic diseases to new areas, it is highly probable; however, it is equally possible that *E. catubrina* is not only a typical parasite of roe deer, but that it also infects elks regardless of the presence of a roe deer population in the studied area. Nevertheless, it is impossible to draw a full conclusion on the basis of this present examination comprising only one animal with no knowledge of the presence of any parasitic infections in other elks from the area, or the health of the local roe deer population. Further analyses of the faecal samples of roe deer and elks from the Kampinos Forest and other parts of Poland are needed.

Infections with coccidia need to be monitored due to their significant impact on animal health. Such an infection might occur as a result of an immune disorder in the examined elk [13] and could imply that the population as a whole is in poor condition. As parasites from the genus *Eimeria* are rare in elks, any observation of *E. catubrina* in an animal from the Kampinos Forest is a matter of concern which merits future investigation.

References

- [1] Chudzicka-Popek M., Goliszewska A., Majdecka T. 2011. Estimation of level of parasites invasion in roe deer (*Capreolus capreolus*) living in Kampinoski National Park. *Annals of Warsaw University of Life Sciences – SGGW Animal Science* 50: 83-88.
- [2] Pilarczyk B., Balicka-Ramisz A., Ramisz A., Lachowska S. 2005. The occurrence of intestinal parasites of roe deer and red deer in the Western Pomerania voivodeship. *Wiadomości Parazytologiczne* 51: 307-310.
- [3] Pyziel A.M., Jóźwikowski M., Demiaszkiewicz A.W. 2014. Coccidia (Apicomplexa: Eimeriidae) of the lowland European bison *Bison bonasus bonasus* (L.). *Veterinary Parasitology* 202: 138-144.
- [4] Pyziel A.M., Demiaszkiewicz A.W. 2013. Coccidia (Apicomplexa: Eimeriidae) of elk (*Alces alces*) in Poland. *Parasitology Research* 112: 2083-2085. doi: 10.1007/s00436-012-3262-6
- [5] Taylor M.A., Catchpole J., 1994. Review article: coccidiosis of domestic ruminants. *Applied Parasitology* 35: 73-86.

- [6] Ziomko I., Cencek T. 1999. *Inwazje pasożytnicze zwierząt gospodarskich. Wybrane metody diagnostyczne*. Drukarnia Piotra Włodarskiego, Warszawa (in Polish).
- [7] Pyziel A.M. 2012. Badania nad kokcydiami z rodzaju *Eimeria*, występującymi u dzikich przeżuwaczy. PhD Thesis, Institute of Parasitology PAS, Poland.
- [8] Golemansky V.G. 1986. Composition, biology and distribution of the coccidians (Coccidia, Eimeriidae) of roe deer (*Capreolus capreolus* L.) in Bulgaria. *Acta Zoologica Bulgarica* 32: 3-10.
- [9] Kuligowska I., Demiaszkiewicz A.W., Kowalczyk R. 2014. A new occurrence of *Eimeria alces* (Apicomplexa: Eimeridae) in elk (*Alces alces*) in East Poland. *Annals of Parasitology* 60: 277-279.
- [10] Arnastauskene T. 1974. Novyj vid kokcidij u losja *Alces alces*. *Acta Parasitologica Lituanica* 12: 39-42.
- [11] Soshkin D.V. 1997. Obnaruzhenie *Eimeria alces* (Eucoccidiida) u losej (*Alces alces*) Brjanskoj oblasti. *Parazitologija* 3: 273-274.
- [12] Pen'kevič V.A. Parazity losja (*Alces alces* L.) Polesskogo radiacionno-ekologičeskogo zapovednika. In: *Materialy 8-j Mezunar. Nauč. Konf., 22-23 mja, 2008, Minsk, Respublika Belarus`. Minsk*. MGCU im. A.D. Saharova: 154.
- [13] Niilo L. 1970. The effect of dexamethasone on bovine coccidiosis. *The Canadian Journal of Comparative Medicine* 34: 325-328.

Received 3 October 2016

Accepted 23 November 2016