

Original papers

Endoparasites of Eurasian lynx (*Lynx lynx*) (Linnaeus, 1758) from an enclosure of Western Pomeranian Nature Society in Jablonowo

Katarzyna J. Filip, Aleksander W. Demiaszkiewicz

W. Stefański Institute of Parasitology, PAS, Twarda 51/55, 00-818 Warsaw, Poland

Corresponding Author: Katarzyna Filip, e-mail: katarzyna.filip@twarda.pan.pl

ABSTRACT. The aim of this study was to describe parasites of three lynx living in an enclosure of Western Pomeranian Nature Society in Jablonowo. During analysis of 3 gram faecal samples eggs of *Toxascaris leonina*, *Toxocara cati*, *Ancylostoma* sp. and oocysts of *Cystoisospora felis* were found. To our knowledge this is the first report of *C. felis* infection in lynx from Poland. Presented research show that wild cats in captivity are particularly exposed on parasitic infections and demand regular examination.

Key words: *Lynx lynx*, endoparasites, *Cystoisospora felis*

Introduction

Eurasian lynx (*Lynx lynx*) (Linnaeus, 1758) is the biggest representative of wild cats in Poland. Population is estimated on 200 individuals, living mostly in Carpathians, northeastern part of the country and Kampinos Forest [1]. Important role in maintenance and reintroduction of this rare species is played by lynx living in captivity. These animals are particularly fragile for infectious diseases, especially parasitic ones. Even parasites typical for lynx have been registered as a cause of animals death and could be an important factor of kittens mortality [2].

Most of data about lynx parasites come from Baltic countries and northern part of Europe [3–5]. Limited population of Eurasian lynx in Poland and their solitary lifestyle make collecting materials for parasitic analysis difficult. As a result, there are only few articles presenting parasites of these animals in the country [6–9].

The aim of this study was to describe parasites of lynx maintained in an enclosure of Western Pomeranian Nature Society in Jablonowo, West Pomerania province. Examined animals are supposed to take part in lynx reintroduction program so their health and condition need to be monitored.

Materials and Methods

Faeces of three lynx living in an enclosure of Western Pomeranian Nature Society in Jablonowo (West Pomerania province) were subjected to coproscopical examination. Two samples were taken directly from the enclosure of male and female kept together and third one was collected from female in another pen. Three grams of each faecal sample were examined using flotation in a sucrose solution, according to Willis, to detect oocysts and eggs of gastrointestinal parasites. Decantation method was performed to find eggs of liver flukes and the Baermann technique was used to detect larvae of lung nematodes [10].

Samples were examined under the light microscope. Eggs and oocysts were identified to a genus or species level using morphological criteria. After analysis of samples, intensity of infection, based on number of eggs and oocysts in 3 grams of faeces, was estimated.

Results and Discussion

Only flotation method revealed the presence of parasite eggs and oocysts. Decantation and the Baermann analysis did not show any trematodes eggs or larvae of lung nematodes.

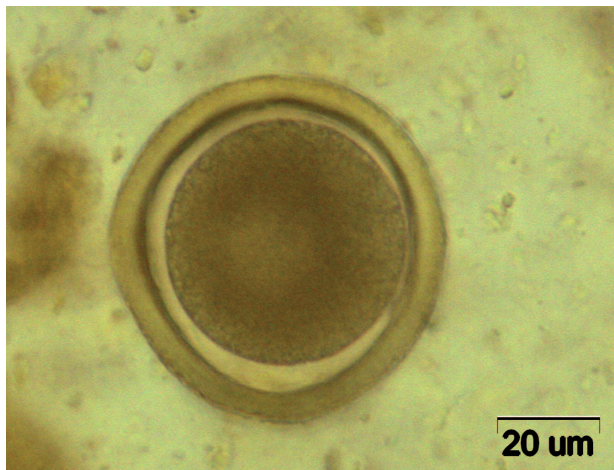


Fig. 1. Egg of *Toxocara cati*

Faeces of two lynx kept together contained approximately 31 and 2 eggs of *Toxocara cati* (Fig. 1), 210 and 11 eggs of *Toxascaris leonina* (Fig. 2), 6 and 14 eggs belonging to the genus *Ancylostoma* (Fig. 3). Third lynx, maintained in another enclosure, was infected with *Cystoisospora felis* (Fig. 4,5) with intensity reaching 4 oocysts in 3

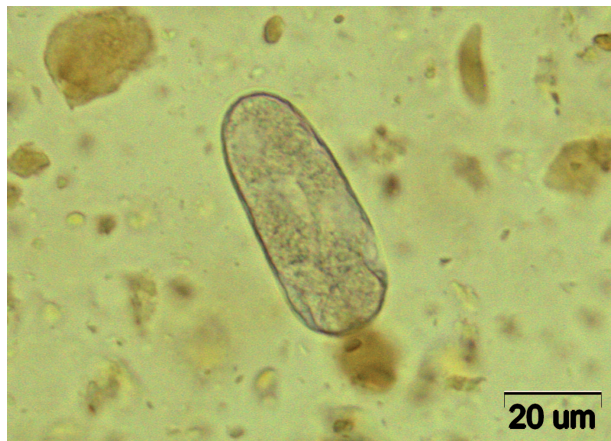

Fig. 3. Egg of *Ancylostoma* sp.

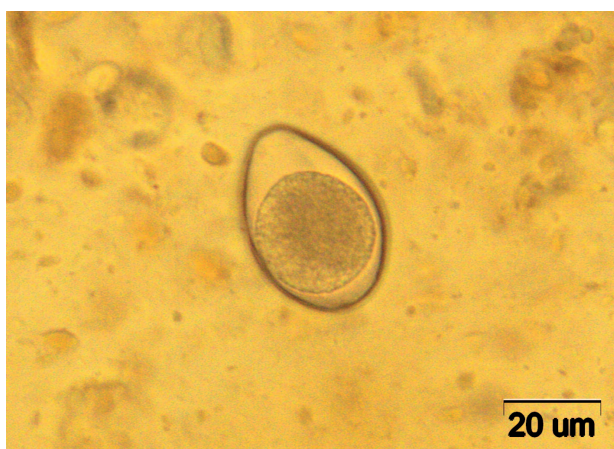

Fig. 4. Oocyst of *Cystoisospora felis*

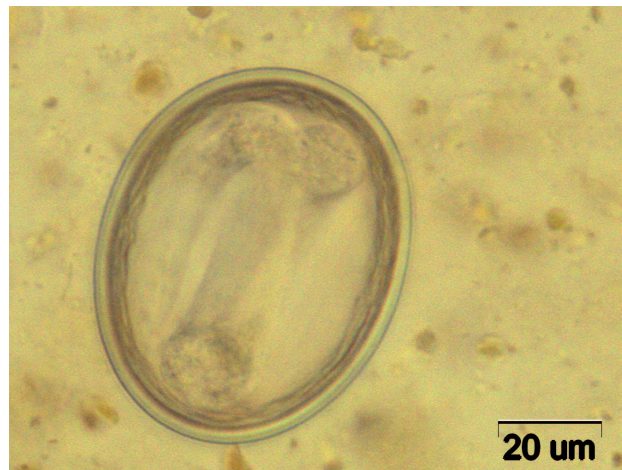

Fig. 2. Egg of *Toxascaris leonina*

gram of faeces. Single egg of *Ancylostoma* sp. was also found.

The most intensive was infection with *T. leonina*. Analysis of faeces revealed the presence of *T. leonina* in two samples from lynx kept together. It is considered to be typical parasite of both feline and canine species [11]. Analysis of faecal samples from wild and domestic carnivorous mammals in Białowieża Forest revealed that 12.5% of dogs and 25% of cats were infected [7]. Despite the fact that it is known to attack also wild animals, *T. leonina* seems to be rare in Eurasian lynx and in natural conditions infects only individuals. So far, it has been registered only in a single lynx from Switzerland [2]. However, according to Okulewicz et al. [12] *T. leonina* infections are especially common and prevalent in large felines from zoological gardens – 57.1% of Felidae, including lynx, from Zoological Garden of Wrocław were infected with this nematode. There are also some data about finding *T. leonina* in snow-leopards from zoological garden in Plock and Warsaw [13]. It is

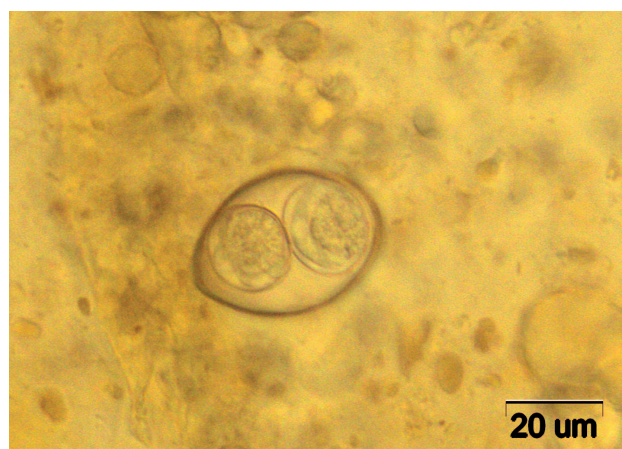

Fig. 5. Oocyst of *Cystoisospora felis* during sporulation

thought that rodents, as intermediate hosts of *T. leonina* play an important role in spreading this parasite on felines [14]. It makes animals living in captivity especially exposed on such infection.

Toxocara sp. is considered to be typical parasite of felines. All parasitological studies of lynx in Poland revealed infection with this nematode. Prevalence varied from 14.7%, 26% to 50% of examined animals [7,6,9]. In Europe, most infections with *T. cati* proceed with high prevalence. It was observed in 71% of animals in Finland [5], 62% in Estonia [3] and almost 40% of lynxes from Switzerland [2]. However, occurrence of *T. cati* in captive felids from Zoological Garden of Wrocław was not so frequent, especially in comparison with *T. leonina* infection [12].

Intensity of infection with *T. cati*, estimated during these studies, was low. Similar results were observed in Estonia and Latvia [3,4], whereas lynx from Finland and Lithuania showed very high level of infection [5,15]. Despite the fact that *Toxocara* sp. seems to be common lynx parasite, there are some reports about clinical cases of toxocarosis in kittens. It has been recognized as a cause of death of two juvenile lynx in Switzerland [2]. Animals suffered from catarrhal enteritis due to massive *Toxocara* infection. Even though, finding eggs of *T. cati* in captive lynx is not surprising, it should not be ignored. Rodents, as a paratenic hosts of *T. cati*, are often the source of infection for wild cats [14].

All examined animals were infected with nematodes from the genus *Ancylostoma*. Intensity of infection was low and varied from 1 to 14 eggs. In Białowieża Forest, Miniuk [9] reported eggs of *Ancylostoma* sp. in two lynx whereas Szczęsna [6] found only two eggs of *A. tubaeforme* in one animal. *Ancylostoma* sp. infection seems to be rare in Eurasian lynx and proceed with low intensity, which was also observed in our study.

Analysis of faecal sample from third lynx revealed the presence of 4 oocysts, belonging to the species *Cystoisospora felis*. To our knowledge, this is the first report of *C. felis* infection in lynx in Poland. So far, it has been found in single serval from Zoological Garden in Warsaw [13]. Coccidial infections were also observed in free-living lynx from Białowieża Forest. Miniuk [9] found oocysts of *Cystoisospora* sp. in the faeces of one lynx from that area and later Górski [7] reported presence of *C. rivolta* in 14,7% of examined wild cats. Both, *C. felis* and *C. rivolta* are considered to be typical for felines. However, in Europe *Cystoisospora* sp. is

registered in Eurasian lynx sporadically, only in single animals from Switzerland (12%) and Finland (0.6%) [2,5]. There are lots of unpublished data from veterinary clinics describing infections with *C. felis* and *C. rivolta* in domestic cats. It could cause clinical coccidiosis, manifesting with diarrhea, which is dangerous especially for young animals and difficult to treat, so occurrence of this parasite demands special attention.

In our study, flotation seems to be more effective method of eggs detecting than decantation. However, Szczęsna [6] during analysis of lynx faeces from Białowieża Forest reported that decantation was more effective as it comes to detection of eggs of gastrointestinal parasites.

Under natural conditions, parasitofauna of Eurasian lynx depends mostly on food habits of animals and prey availability in the environment [16]. However, lynx living in captivity are exposed on a completely different factors determining parasite diversity and level of infections. They are subjected to a close contact with other animals, like rodents which are considered to spread some parasitoses on wild cats. Living in a closed, restricted area encourage intensive parasite infections and might be a threat for lynx health. Therefore, it is extremely important to examine animals living in captivity on the presence of parasites and regularly deworm them with proper antihelmintics.

References

- [1] Jędrzejewski W., Nowak S., Schmidt K., Jędrzejewska B. 2002. Wilk i ryś w Polsce – wyniki inwentaryzacji w 2001 roku [The wolf and the lynx in Poland – results of a census conducted in 2001]. *Kosmos* 51: 491-499 (in Polish with summary in English).
- [2] Schmidt-Posthaus H., Breitenmoser-Wörsten C., Posthaus H., Bacciarini L., Breitenmoser U. 2002. Causes of mortality in reintroduced eurasian lynx in Switzerland. *Journal of Wildlife Diseases* 38: 84-92. doi:10.7589/0090-3558-38.1.84
- [3] Valdmann H.E., Moks E., Talvik H. 2004. Helminth fauna of Eurasian lynx (*Lynx lynx*) in Estonia. *Journal of Wildlife Diseases* 40: 356-360. http://dx.doi.org/10.7589/0090-3558-40.2.356
- [4] Bagrade G., Vismanis K., Kirjusina M., Ozolins J. 2003. Preliminary results on the helminthofauna of the Eurasian lynx (*Lynx lynx*) in Latvia. *Acta Zoologica Lituanica* 13: 5-7. http://dx.doi.org/10.1080/13921657.2003.10512536
- [5] Deksne G., Laakkonen J., Näreaho A., Jokelainen P., Holmala K., Kojola I., Sukura A. 2013. Endoparasites

- of the Eurasian lynx (*Lynx lynx*) in Finland. *Journal of Parasitology* 99: 229-234. doi:10.1645/GE-3161.1
- [6] Szczęsna J., Popiołek M., Schmidt K., Kowalczyk R. 2008. Coprological study on helminth fauna in Eurasian Lynx (*Lynx lynx*) from the Białowieża Primeval Forest in Eastern Poland. *Journal of Parasitology* 94: 981-984.
<http://dx.doi.org/10.1645/GE-1440.1>
- [7] Górski P., Zalewski A., Łakomy M. 2006. Parasites of carnivorous mammals in Białowieża Primeval Forest. *Wiadomości Parazytologiczne* 52: 49-53.
- [8] Fagasiński A. 1961. A contribution to the knowledge of helminth fauna of the lynx and wildcat in Poland. *Acta Parasitologica Polonica* 9: 1-6.
- [9] Miniuk M. 1996. Przegląd pasożytów wybranych gatunków ssaków łownych i chronionych w Puszczy Białowieskiej. *Sylwan* 140: 87-95 (in Polish).
- [10] Ziomko I., Cencek T. 1999. Inwazje pasożytnicze zwierząt gospodarskich. Wybrane metody diagnostyczne. Drukarnia Piotra Włodarskiego, Warszawa: 12-16, 20 (in Polish).
- [11] Okulewicz A., Perec-Matysiak A., Buńkowska K., J. Hildebrand J. 2012. *Toxocara canis*, *Toxocara cati* and *Toxascaris leonina* in wild and domestic carnivores. *Helmintologia* 49: 3-10.
- [12] Okulewicz A., Lonc E., Borgsteede F.H.M. 2002. Ascarid nematodes in domestic and wild terrestrial mammals. *Polish Journal of Veterinary Sciences* 5: 277-281.
- [13] Bartosik J., Górski P. 2010. The intestinal parasites of the selected mammal species, living in zoological gardens and wild animal parks. *Roczniki Naukowe Polskiego Towarzystwa Zootechnicznego* 6: 143-150.
- [14] Okulewicz A. 2008. Rola żywicieli paratenicznych w cyklach rozwojowych helmintów [The role of paratenic hosts in the life cycles of helminths]. *Wiadomości Parazytologiczne* 54: 297-301 (in Polish with summary in English).
- [15] Kazlauskas J., Matusевичius A. 1981. Parasite fauna of lynx in Lithuania. *Acta Parasitologica Lithuanica* 19: 8-11.
- [16] Ryser-Degiorgis M.P. 2009. Causes of mortality and diseases of Eurasian lynx (*Lynx lynx*). In: *Iberian Lynx ex situ Conservation: an interdisciplinary approach*. (Eds. A. Vargas, C. Breitenmoser-Würsten, U. Breitenmoser), Madrid: Fundación Biodiversidad in collaboration with: IUCN Cat Specialist Group: 275-289.

Received 01 February 2017

Accepted 20 March 2017