

Original papers

Nematodes of the large intestine of the European bison of the Białowieża National Park

Aleksander W. Demiaszkiewicz, Anna M. Pyziel, Izabela Kuligowska,
Jacek Lachowicz, Michał K. Krzysiak¹

W. Stefański Institute of Parasitology, Polish Academy of Sciences, 51/55 Twarda Street, 00-818 Warszawa, Poland
¹Białowieża National Park, Park Pałacowy, 17-230 Białowieża, Poland

Corresponding author: A.W. Demiaszkiewicz; E-mail: aldem@twarda.pan.pl

ABSTRACT. The present study was conducted on 31 males and females of the European bison, eliminated during the winter seasons 2007–2011 in the Białowieża Primeval Forest, Poland. The caeca of 14 free-ranging bison, aged from 3 months up to 16 years, the most favorable infection site for the large intestine nematodes, were investigated during the winter of 2007/2008. The parasitological autopsies of the large intestines of 9 free-ranging bison aged from 5 months up to 10 years as well as 9 bison kept in the close reserves aged from one up to 20 years were done during the winter seasons of 2008–2011 to determine localization of nematodes in large intestine and the total intensity of parasite infection. Five species of nematodes (i.e., *Trichuris ovis*, *Oesophagostomum venulosum*, *O. radiatum*, *Ashworthius sidemi*, *Nematodirus helvetianus*) were found in dissected caecum of bison culled during the winter of 2007/2008. During the seasons of 2008–2010, 6 species of nematodes were found in the large intestine of bison (i.e., *T. ovis*, *O. venulosum*, *O. radiatum*, *A. sidemi*, *N. roscidus* and *Bunostomum trigonocephalum*). We did not find any nematodes in the lumen of the large intestine of captive bison culled during the seasons of 2010/2011. The results of the present study indicate that the intensity of infection by the large intestine nematodes of the European bison in the Białowieża Primeval Forest has stayed at the comparable level throughout the last 20 years; however the number of nematode species has increased. The observed level of parasitic infection is typical of subclinical parasitoses.

Key words: nematodes, large intestine, *Bison bonasus*, Białowieża Forest

Introduction

Studies on nematodes inhabiting the large intestine of the European bison are very rare, because of the great volume of the intestinal content, and difficulties and laboriousness of the investigations. The most numerous parasites occurring in the large intestine of large ruminants represent the genera *Trichuris* and *Oesophagostomum* – and they are responsible for serious parasitic diseases in domestic animals.

Trichuriasis is one of the most important parasitosis, caused in cattle and sheep by nematodes belonging to the species of *Trichuris ovis*. Low intensity of infection has asymptomatic course. Intensive invasions cause clinical symptoms such as diarrhea (sometimes bloody), lack of appetite,

anemia, weakness, and loss of body mass. The mucosa of the large intestine is then edematous, covered by a lot of mucus, and showing signs of catarrhal inflammation. Sometimes petechiae and hemorrhagic foci were also observed. Finally, ulceration of mucosa appears, as a result of secondary infection.

Another parasitosis of the large intestine of ruminants is oesophagostomiasis, which is caused by nematodes from the genus *Oesophagostomum*. It is caused by two species of nematodes: *O. radiatum* – typical parasite of cattle, and *O. venulosum* – typical parasite of sheep and cervids. In the histotropic phase an acute course of disease is observed, which is manifested by an intensified peristaltic, intensive diarrhea with the addition of mucus and blood in faeces, and a colic pains. Moreover, the lack of

appetite, anemia and wasting can occur. In the mucosa of large intestine, and rarely of small intestine, numerous nodules of different size – up to 10 mm, containing the larvae of nematodes, can be found. Mucosa near the nodules shows attributes of inflammation and infiltration with eosinophils, and the presence of ecchymoses and fibrinous deposits. In the older nodules abandoned by larvae, crater-like opening on the top with the caseous mass can be seen. In the case of bacterial infection, noduli can be suppurated. Intensive invasions can cause wide changes as colonitis ulcerans [1–3]. Lack of actual information related to the level of nematode infection of the large intestine in European bison was the reason to undertake the present study.

Materials and methods

Examinations were conducted on 31 bison of both sexes during winter eliminations in the Białowieża Forest during the years of 2007–2011. During the winter season of 2007/2008 14 free-ranging European bison at the age from 3 months up to 16-year old were examined. To estimate the species composition of nematodes of the large intestine of bison, the caeca from examined individuals were taken, as they are the preferable location for the parasites. The whole caeca were taken from calves, whereas only 1/3 of caecal content was taken from the adults, because of the great volume of their caecum. Nine free-ranging bison at the age from 5 months up to 10-year old were examined during the winter of 2009/2010, and 9 bison from the close reserves at the age from 1 up to 20-year old during the winter of 2010–2011. Then, to estimate the exact location of parasites and the intensity of infection, the whole large intestines, and caecum with colon were taken from all examined bison. Guts without mesentery were parasitologically necropsied and the content was subjected to sedimentation. The sediment was preserved with 2% formaldehyde, and then the small portions of it were examined in Petri dishes with the addition of water to isolate all nematodes; then the fluid was replaced to the mixture of 75% ethanol and 5% addition of glycerol. After evaporation of alcohol, non permanent preparations were made from all selected worms to establish the species identification.

Results

In caecum of the bison culled during the winter of 2007/2008 5 species of nematodes were found: *Trichuris ovis*, *Oesophagostomum venulosum*, *O. radiatum*, *Ashworthius sidemi* and *Nematodirus*




Fig. 1. The anterior end of *Oesophagostomum venulosum*

helvetianus. *O. venulosum* (Fig. 1) was the most prevalent species, and was found in 71% of the examined bison. Intensity of infection varied from 1 up to 66 specimens, and the average intensity of infection was 21. *T. ovis* (Fig. 2) occurred in 43% of bison, whereas the intensity of infection in an individual animal ranged from 8 up to 849 specimens of worms and the mean intensity of infection was 237 specimens. Two species of nematodes, i.e., *O. radiatum* and *A. sidemi*, were

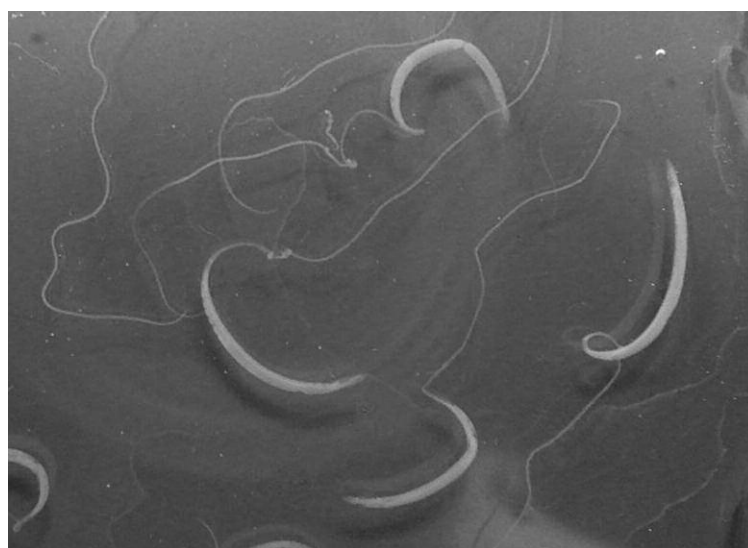

Fig. 2. Females of *Trichuris ovis*

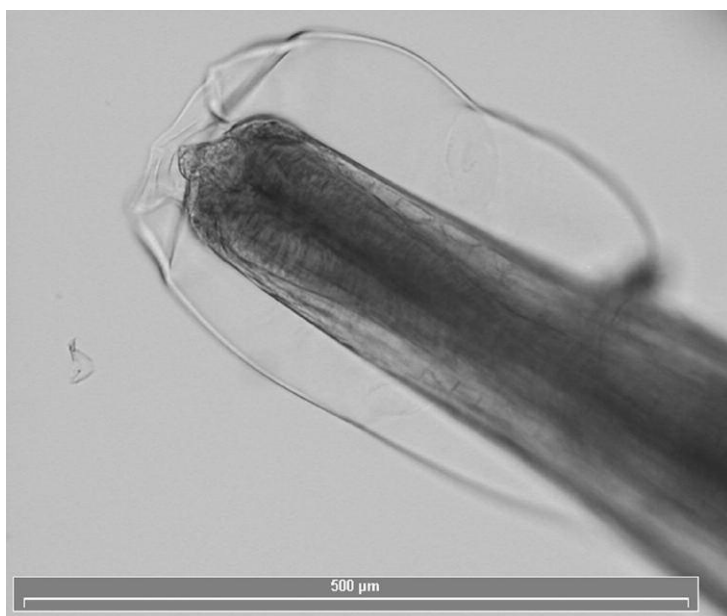


Fig. 3. The anterior end of *Oesophagostomum radiatum*

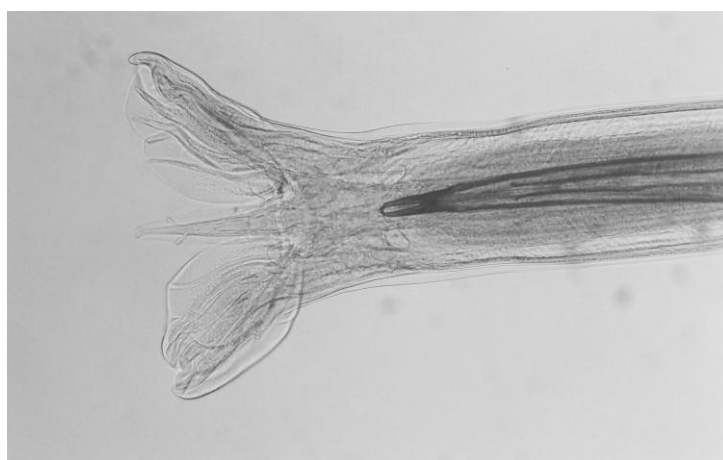


Fig. 4. Bursa copulatrix of *Ashworthius sidemi*

found in caecum in 14% of examined animals. Intensity of infection with *O. radiatum* (Fig. 3) ranged from 2 up to 42 specimens, and mean intensity of infection was 22 worms. Intensity of

Table 1. The level of infection with the large intestine nematodes of free-ranging European bison during the winter of 2007/2008

Species of nematodes	Prevalence (%)	Intensity of infection	
		Range	Mean
<i>Oesophagostomum venulosum</i>	71	1–66	21
<i>Oesophagostomum radiatum</i>	14	2–42	22
<i>Trichuris ovis</i>	43	8–849	273
<i>Ashworthius sidemi</i>	14	3–21	12
<i>Nematodirus helvetianus</i>	7	13	13

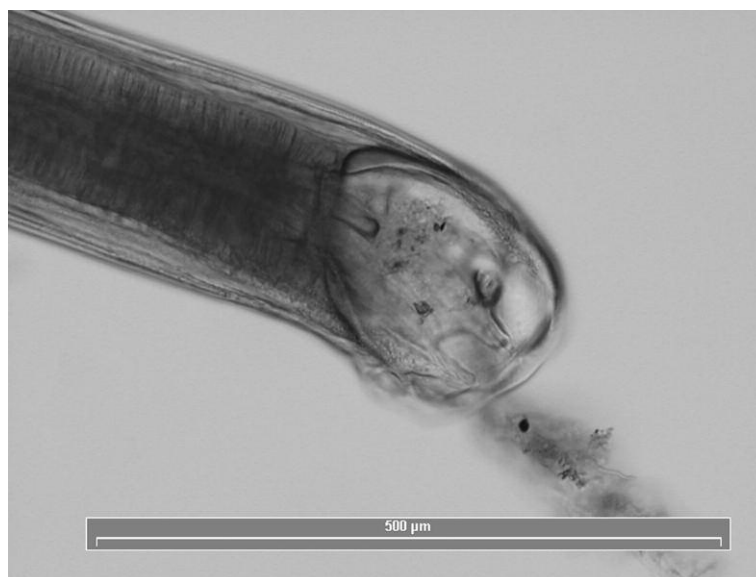

Fig. 5. The anterior end of *Bunostomum trigonocephalum*

infection with *A. sidemi* (Fig. 4) in the caecum of bison varied from 3 to 21 specimens, and mean intensity of infection was 12 nematodes. Nematodes of *N. helvetianus* were found only in the caecum of one bison at the level of 13 specimens (Table 1). In the studies done during the winter of 2009/2010 all of the examined bison were infected by nematodes of the genera *Trichuris* and *Oesophagostomum*. In the whole large intestines, the range of intensity of infection with *T. ovis* was from 60 up to 777 worms, and the mean intensity of infection was 368 nematodes. However, *Trichuris* most frequently occurred in caecum within the range of 48 to 544 nematodes, and their mean number was 242 specimens. In colon the number of parasites was lower, the range of intensity of infection varied from 12 to 314 specimens, with the mean intensity of infection 126 parasites. Nematodes of *O. venulosum* were also found in the large intestine. The range of the intensity of infection with these nematodes was from 37 to 289 specimens, and the mean intensity of infection was 98 specimens. This species, like the previous one, placed for the most parting caecum, was with the intensity of infection from 20 to 127 specimens, with the mean intensity of infection of 61 nematodes. The next species, *O. radiatum* occurred in all large intestines in intensity of infection from 1 up to 809 nematodes, and mean intensity of infection was 122 specimens. However, this parasite contrary to the previously mentioned was found mainly in the colon at the intensity of infection from 1 to 808 nematodes, and the mean intensity of infection was 116 specimens. In the

Table 2. The level of infection with the large intestine nematodes of free-ranging European bison during the winter of 2009/2010

Species of nematodes	Prevalence (%)	Intensity of infection	
		Range	Mean
<i>Trichuris ovis</i>	100	60–777	368
<i>Oesophagostomum venulosum</i>	100	37–289	98
<i>Oesophagostomum radiatum</i>	100	1–809	122
<i>Ashworthius sidemi</i>	44	1–4	2
<i>Nematodirus roscidus</i>	22	1–14	7
<i>Bunostomum trigonocephalum</i>	22	1–4	2

caecum were found only a few nematodes of *O. radiatum* at the range of intensity of infection from 1 up to 39 specimens, and mean intensity of infection was 6 nematodes. Moreover, in 4 examined bison there were found not numerous (1–4 specimens) nematodes of *A. sidemi*, and in 2 bison nematodes of *N. roscidus* (1 and 14 specimens). In addition, in 2 bison a single individual of *B. trigonocephalum* (Fig. 5) was found (Table 2). No nematodes were found in the large intestines of the bison from the close reserves examined during the winter season of 2010/2011.

Discussion

The first information about the occurrence of mentioned nematodes in the bison can be found in the monograph by Wróblewski [4], who had observed in caecum „great number of *Trichocephalus*”. Then, *post mortem* examinations of 25 bison in closed reserves in the large intestine were found only nematodes of *O. radiatum* and of *T. ovis* [5]. In subsequent examinations of caecum of 4 bison in freedom [6] in all animals were found *O. radiatum*, and only in one *O. venulosum* and *Chabertia ovina*. In mentioned studies the intensity of infection was not defined. Further examinations were made in the beginning of winter of 1987/1988, parasitological necropsies of the large intestine of 6 bison, and in the end of this winter 9 bison. There were found 4 species of nematodes: *Ch. ovina*, *O. radiatum*, *O. venulosum* and *T. ovis*. Species *Ch. ovina* appeared in the end of winter period in significant percent of animals, but intensiveness of this infection was low. However, in the end of

winter raised distinctly the intensity of 3 remaining species of nematodes. In the comparison with the bison from closed reserves those in freedom assimilated *O. venulosum* and *Ch. ovina*. One should suppose that the places of supporting winter feeding are the sources of infection. Lots of faeces with invasive stadia of parasites are collected from such places. Bison can get infected on the pastures of neighboring villages infected by cattle and sheep kept there [7]. In comparison with the results of examinations done in winter 1987/1988 [7] in presented studies helminth fauna of the large intestine enriched for four species: *A. sidemi*, *N. helvetianus*, *N. roscidus* and *B. trigonocephalum*. There were not found observed earlier nematode *Ch. ovina*. The presence of *A. sidemi* – typical parasites of the abomasum, and *N. helvetianus* as well as *N. roscidus* – parasites of duodenum in the large intestine are caused by a very high intensity of infection of these parasites at their typical infection site, and then their excessive density and dispersion on farther parts of digestive tract [8]. Registration of *B. trigonocephalum* – typical parasites of moose can be caused by the increased numbers and penetration of bison biotopes by moose. Found in the winter season of 2007/2008 lower intensity of infection is caused by the fact that in studies were examined only caeca, and in the years of 1987/1988 whole large intestines. The absence of nematodes of *Ch. ovina* in our examinations can be due to stopping of cattle and sheep husbandry in woodland villages and the lack of contact of bison with the invasive forms of this parasite. Comparing our results to those from 20 years ago [7], the maximum intensity of infection by nematodes of *T. ovis* is now lower, but the mean intensity of infection remains this same level. The maximal intensity among nematodes from the genus *Oesophagostomum* slightly decreased. The mean intensity of *O. radiatum* infection decreased more than twice. However, in case of *O. venulosum* the maximal intensity of infection increased 3 times, and the mean intensity for 50%. This situation can be explained by reduction of contact of bison with cattle, typical host of *O. radiatum*, and the adaptation of *O. venulosum* from cervids. Studies carried out in Belarussian part of the Białowieża Forest from 1986 to 2001 showed that 38% of examined bison had infections with nematodes of the large intestines. Twenty percent of these animals were infected with nematodes belonging to the genus *Oesophagostomum*, and 25% with *Trichuris*. The

mean intensity of infection of bison with *Trichuris* was 153 specimens, and was over two times higher than in presented studies. The highest intensity of infection (1049 trichocephalides) was found in 9-months old calf of bison with clinical symptoms such as wasting, diarrhea, and dermal changes [9,10]. Course of invasion of *T. ovis* with clinical symptoms causing death was observed also in moose. During *post mortem* examinations in the large intestine were found more than 5 thousands of nematodes [11]. Lower prevalence and intensity of infection with nematodes of the large intestine of Belarussian bison were caused by lower number and density of these animals at the time of examinations. The annual effective anthelmintic treatment of the bison kept in the close reserves of the Białowieża National Park, which has been hold for many years, is the reason for the lack of nematodes in the large intestines of 9 examined captive bison [12–15].

The level of infection of free-ranging bison in the Białowieża Forest with the large intestine nematodes during the last 20 years remains similar; however, the species composition of parasites increased. The observed intensity of infection is characteristic for subclinical invasions. Diarrheas caused by the aforementioned nematodes can be dangerous for late born, weak calves.

References

- [1] Furmaga S. 1983. Choroby pasożytnicze zwierząt domowych. PWRiL, Warsaw.
- [2] Love S.C.J., Hutchinson G.W. 2003. Pathology and diagnosis of internal parasites in ruminants. In: *Gross pathology of ruminants, Proceedings 350, Post Graduate Foundation in Veterinary Science*. University of Sydney: 309-338.
- [3] Taylor M.A., Coop R.L., Wall R.L. 2007. *Veterinary Parasitology*. Blackwell Publishing, Oxford.
- [4] Wróblewski K. 1927. *Żubr Puszczy Białowieskiej*. Wydawnictwo Polskie, Poznan.
- [5] Drózdź J. 1961. A study on helminths and helminthiasis in bison, *Bison bonasus* (L.) in Poland. *Acta Parasitologica Polonica* 9: 55-96.
- [6] Drózdź J., Demiaszkiewicz A.W., Lachowicz J. 1989. The helminth fauna of free-ranging European bison, *Bison bonasus* (L.). *Acta Parasitologica Polonica* 34: 117-124.
- [7] Drózdź J., Demiaszkiewicz A.W., Lachowicz J. 1990. Nicienie jelita grubego żubrów. *Wiadomości Parazytologiczne* 38: 35-38.
- [8] Demiaszkiewicz A.W., Lachowicz J. 2007. Wzrost zarażenia żubrów helmintami w Puszczy Białowieskiej. In: *Rola hodowli ex situ w procesie restytucji żubra*. (Ed. W. Olech). Lasy Państwowe, Gołuchów: 12-16.
- [9] Kochko Yu.P. 2003. Podsumowanie aktualnej sytuacji helmintologicznej żubrów w Puszczy Białowieskiej. In conference materials: „Znaczenie badań naukowych dla ochrony żubrów w Polsce”. Warszawa, 13.06.2003: 18-19.
- [10] Kochko Yu.P. 2004. Parazitarnye bolezni zubrov. In: *Ekologiceskie i veterinarnye aspekty zubrov w Belarusi*. (Ed. P.A. Krasochko). Biznesofset, Minsk: 210-235.
- [11] Skrjabin K.I., Shihobalova H.P., Orlov I.V. 1957. *Osnovy Nematodologii*. Izdatielstvo Akademya Nauk SSSR, Moskva.
- [12] Demiaszkiewicz A.W., Drózdź J., Lachowicz J., Krasieński Z. 1999. Przydatność Vermitanu w leczeniu helmintoz żubrów w rezerwach Białowieskiego Parku Narodowego. *Magazyn Weterynaryjny* 8: 118-119.
- [13] Demiaszkiewicz A.W., Krasieński Z., Drózdź J., Lachowicz J. 1997. Skuteczność preparatu Ivomec Premix w zwalczaniu helmintoz żubrów w rezerwach Białowieskiego Parku Narodowego. *Magazyn Weterynaryjny* 6: 366-367.
- [14] Demiaszkiewicz A.W., Krzysiak M.K., Pyziel A.M., Kuligowska I., Lachowicz J. 2010. Skuteczność odrobaczenia dzikich przeżuwaczy utrzymywanych w Rezerwacie Pokazowym Białowieskiego Parku Narodowego. *Życie Weterynaryjne* 85: 532-534.
- [15] Krzysiak M.K., Demiaszkiewicz A.W., Lachowicz J., Pyziel A.M., Kuligowska I. 2012. Skuteczność odrobaczania żubrów utrzymywanych w Rezerwach Hodowlanych Białowieskiego Parku Narodowego. *Życie Weterynaryjne*: 87: 47-48.

Received 20 January 2012

Accepted 25 February 2012