

## Review article

# Warm-region parasites invasion in temperate climate countries

Bartosz KASZUBSKI, Oskar SZYMAŃSKI, Aleksandra SĘDZIKOWSKA

Department of General Biology and Parasitology, Medical University of Warsaw, Poland

Corresponding Author: Bartosz Kaszubski; e-mail: bartoszkaszubski123@gmail.com

**ABSTRACT.** Long-term changes in weather conditions on Earth have a significant impact on the world around us. These include not only increasingly extreme weather events such as droughts and heatwaves. These effects can be felt throughout the natural environment, influencing the spread of parasites and the diseases they transmit. Climate change can alter the range and life cycles of parasites, and accelerate and lengthen the activity period of vectors. Four species are described in this manuscript: *Balamuthia mandrillaris*, *Naegleria fowleri*, *Trypanosoma cruzi* and *Strongyloides stercoralis*. *Balamuthia mandrillaris* is a species of an opportunistic cyst-forming free-living amoeba. The main habitat is moist soil and freshwater reservoirs. It could be pathogenic to humans. The amoeba consumes cutaneous tissue and excretes enzymes leading to an immune response of the host. *Naegleria fowleri* is a free-living amoeba that might cause primary amoebic meningoencephalitis (PAM) whose mortality rate reaches as much as 98%. Trophozoites enter the body through the nasal cavity while underwater. Most often cases of PAM include immunocompetent children and young adults. *Trypanosoma cruzi* is a flagellate protozoan with life cycle between hematophagous insects of the Triatominae subfamily and various mammal species including human. *Trypanosoma cruzi* causes the Chagas disease (American trypanosomiasis). Strongyloidiasis, caused by the parasite *Strongyloides stercoralis*, is a neglected tropical disease (NTD). Infection starts when the host walks barefoot on soil contaminated with filariform larvae that penetrate the skin. Immunosuppression in infected patients can lead to hiperinfection and death.

**Keywords:** *Balamuthia mandrillaris*, *Naegleria fowleri*, *Trypanosoma cruzi*, *Strongyloides stercoralis*, opportunistic amoeba

## Introduction

Global warming could significantly impact parasite-host relationships and the transmission of parasitic diseases. Changes in temperature, precipitation, and other climatic factors could alter their distribution, leading to an increased incidence and geographic spread of some parasitic diseases [1–3]. In our manuscript we focused on four species of parasites: *Balamuthia mandrillaris*, *Naegleria fowleri*, *Trypanosoma cruzi* and *Strongyloides stercoralis*.

### *Balamuthia*

*Balamuthia mandrillaris* is a species of an opportunistic cyst-forming free-living amoeba. The main habitat is moist soil and freshwater reservoirs. It could be pathogenic to humans and cause

balamuthia amoebic encephalitis (BAE). There have been confirmed cases in Europe, China, Japan, India, Thailand, South Korea and Australia [4–6]. Out of 300 described cases, most of them have been reported in the US and Peru [7]. The ability of *B. mandrillaris* to infect humans is a multifactorial process and is dependent on its ability to survive outside the host for various times and environmental conditions like temperature. Upon axenic cultivation, amoebae grew at temperatures ranging from 25°C to 37°C and remained viable for up to several months [8]. The incidence of BAE is expected to increase due to rising temperatures caused by climate change [9].

Infection proceeds through contact with its environment via skin wounds, respiratory tract [10] or eyes [11]. It can also be transmitted through organ transplants [12–14]. *B. mandrillaris* has two

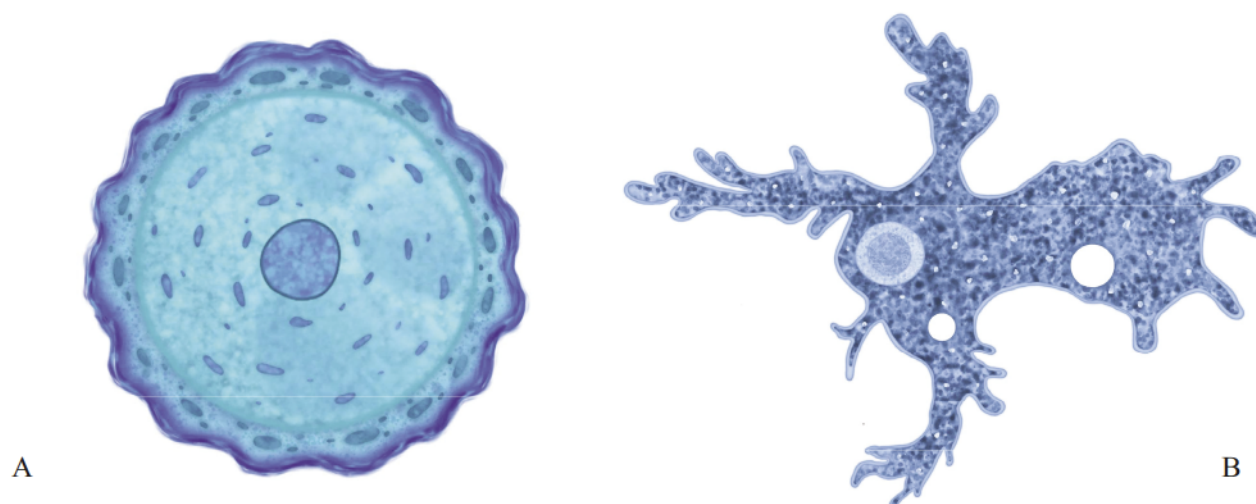


Figure 1. *Balamuthia mandrillaris* cyst (A) and trophozoite (B) (drawn by Oskar Szymański)

morphologic forms (Fig. 1): an uninucleate trophozoite (B) ranges in size from 12–60  $\mu\text{m}$ , and spherical cyst (A) 12–30  $\mu\text{m}$  [15].

*Balamuthia mandrillaris* was discovered in a brain of a mandrill monkey (*Mandrillus sphinx*) in San Diego Zoo Wild Animal Park in 1986 after it died from meningoencephalitis [16]. In humans retrospective analysis from 1974 to 1989 confirmed that this amoeba causes BAE – a type of granulomatous encephalitis caused by the amoeba, in both healthy and immunocompromised individuals [15].

In 1995 the first case was reported in Czech Republic – a boy (3 years and 9 months), who has never travelled abroad. He died because of brain lesions, specific diagnosis through biopsy (indirect immunofluorescence) confirmed that the lesions were caused by *B. mandrillaris* [17]. It was the first European case of *B. mandrillaris* infection, previous cases were described in warmer regions e.g. Africa, Australia also the Americas [18]. Reported cases of BAE often involve children, in China, 56% of the thirty-two confirmed cases we diagnosed in children [19].

A study from 2010 through checking isolates from swiss water reservoirs showed that one of the samples displayed a cytotoxic profile comparable to one of the potentially pathogenic free-living amoebae (which included *B. mandrillaris*). But there were no further tests to prove which species of free-living amoeba (FLA) was exactly found [20].

In 2015 in the Netherlands a case of a 61 year old woman who had travelled earlier to Gambia was described. She died because of BAE the same year but it was not confirmed whether she was infected in Africa or in the Netherlands [21].

#### *Symptoms and pathogenesis*

In patients from Peru cutaneous type of balamuthiasis was reported [22]. The amoeba consumes cutaneous tissue and excretes enzymes leading to an immune response of the host. This cascade leads to necrosis, granulomas, haemorrhage and lesions [10].

The CNS infection manifests itself through haemorrhagic necrosis in the cerebrum, midbrain, thalamus, brain stem, and cerebellum. First symptoms are non-specific and are easy to misdiagnose, it could be headache, photophobia, myalgia, nausea, low-grade fever. When the amoeba reaches the CNS, symptoms might become more severe [22]. Patients and medical personnel have reported behavioral changes, speech defects, and focal seizures [23,24]. Finally, the spreading necrosis might cause paralysis and coma. In the end, BAE leads to death in most cases. Most patients who show up with skin lesions caused by balamuthiasis usually end up with the cerebral form of infection. This progression might range from weeks to years (the most extreme case – a patient from Peru whose infection did not progress for 8 years) [22].

#### *Diagnosis*

According to Bhosale and Parija [10] the most effective procedure in diagnosing balamuthiasis is through a biopsy of a skin lesion. It can also prove successful when performed on the lungs or sinuses. The biopate should be fixed in formalin and stained with either HE, Giemsa or acid Schiff stains to indicate *Balamuthia* trophozoites. Calcofluor white is suggested in staining *Balamuthia* cysts. These authors also recommend culturing and PCR of the

cerebrospinal fluid (CSF) as supportive assays. As the authors points out it is important not to mistake the trophozoites of *Balamuthia* for human macrophages or keratinocytes which were affected by necrosis. Granulomas with CD4 and CD8 T-cells, B-lymphocytes, few plasma cells, macrophages, and multinucleated giant cells are often observed [10].

Other authors such as Visvevara et al. [18] argue that the golden standard for *Balamuthia* diagnosis comes down to indirect immunofluorescent staining (IIF) of brain tissue sections using anti-*Balamuthia* sera raised in rabbits. CSF analysis might show lymphocytic pleocytosis with elevated protein ( $\geq 40$  mg/dl) and normal-to-low glucose [22]. ELISA and flow cytometry to identify anti-*B. mandrillaris* antibodies are helpful [25–27].

Wang et al. [6] recommend neuroimaging as a supportive diagnostic tool, which may help find characteristic brain lesions and assess the progression of the disease. Neuroimaging can show lesions although the findings are usually nonspecific and are not useful in diagnosing balamuthiasis. The haemorrhagic lesions appear: T1 – hypodense and T2 – hyperintense [6,28].

Molecular diagnosis is based on multiplex and nested real-time PCR to detect *B. mandrillaris* in CSF, vitreous fluid, tissue biopsy samples, soil, water, and archived paraffinized tissue samples. During the reaction specific for *B. mandrillaris* sequences are amplified: mitochondrial 16S rRNA gene, nuclear 18S rRNA gene and RNase P gene [10].

As Bravo et al. [29] emphasizes the diagnosis of *Balamuthia* infection requires attention because the symptoms may be too subtle or non-specific. Facial skin lesions require differential diagnosis due to the possibility of other infections such as leishmaniasis, sporotrichosis, lupus vulgaris, sarcoidosis, granuloma faciale or basal cell carcinomas.

The differentiation of skin infections other than on the face is with leprosy, granuloma annulare, mycosis fungoides, and necrobiosis lipoidica. In the case of BAE, the differential diagnosis is with neurotuberculosis, neurocysticercosis, fungal infections, neoplasms, viral meningoencephalitis, and acute disseminated encephalomyelitis [10].

The correct diagnosis of balamuthiasis requires the diagnostician to have extensive knowledge of opportunistic amoebae and to look very carefully at each case being examined.

### Treatment

The non-specific symptoms can cause the use of wrong medication for balamuthiasis. There have been reported cases of using steroids, antifungals, antibiotics and antivirals which have proven ineffective. Anti-inflammatory medication has also been reported to cause faster exploration of the amoeba through the patient's body [10,22]. According to Bhosale and Parija (2021), the drugs used in treatment are: amphotericin B, sulfadiazine, flucytosine, fluconazole, azithromycin, clarithromycin, miltefosine.

The treatment of balamuthiasis depends highly on the early diagnosis. Unfortunately, the difficulty in diagnosis leads to high mortality rate. A significant part of the drugs which have been proven effective against *Balamuthia* show detrimental side effects. This occurrence seems to be associated with their lack of organ specificity and penetration through the blood–brain barrier (BBB). The current way of solving these problems focuses on conjugating said drugs with nanoparticles to help bioavailability [30]. Azithromycin and pentamidine *in vitro* showed promising results, though the patient died, the postmortem analysis showed degradation of the amoebae [31].

### *Naegleria fowleri*

#### Characteristic

*Naegleria fowleri* is a free-living amoeba known as the “brain-eating amoeba”. *Naegleria fowleri* is found in air, soil or warm water [32] and could cause primary amoebic meningoencephalitis (PAM). *N. fowleri* is an example of a free-living amoeba that is significantly affected by climate change [33]. The Minnesota case of *N. fowleri* in a patient described by Kemble et al. [34] occurred 550 miles north of the northernmost case in America. Authors suggested that *N. fowleri* can occur in areas at much higher latitudes than previously reported because of weather conditions and long-term climate change. Other authors noticed more cases of PAM especially since year 2000, pointing out, that its actual incidence will increase due to climate change [35].

Primary amoebic meningoencephalitis (PAM) is characterized by mortality rate reaching as much as 98% [36]. In most cases death occurs 7–10 days after infection. Because the disease does not spread very easily, therefore few cases are reported and can be mistaken with other pathogenic organisms. This amoeba has three stages (Fig. 2): cysts (A),

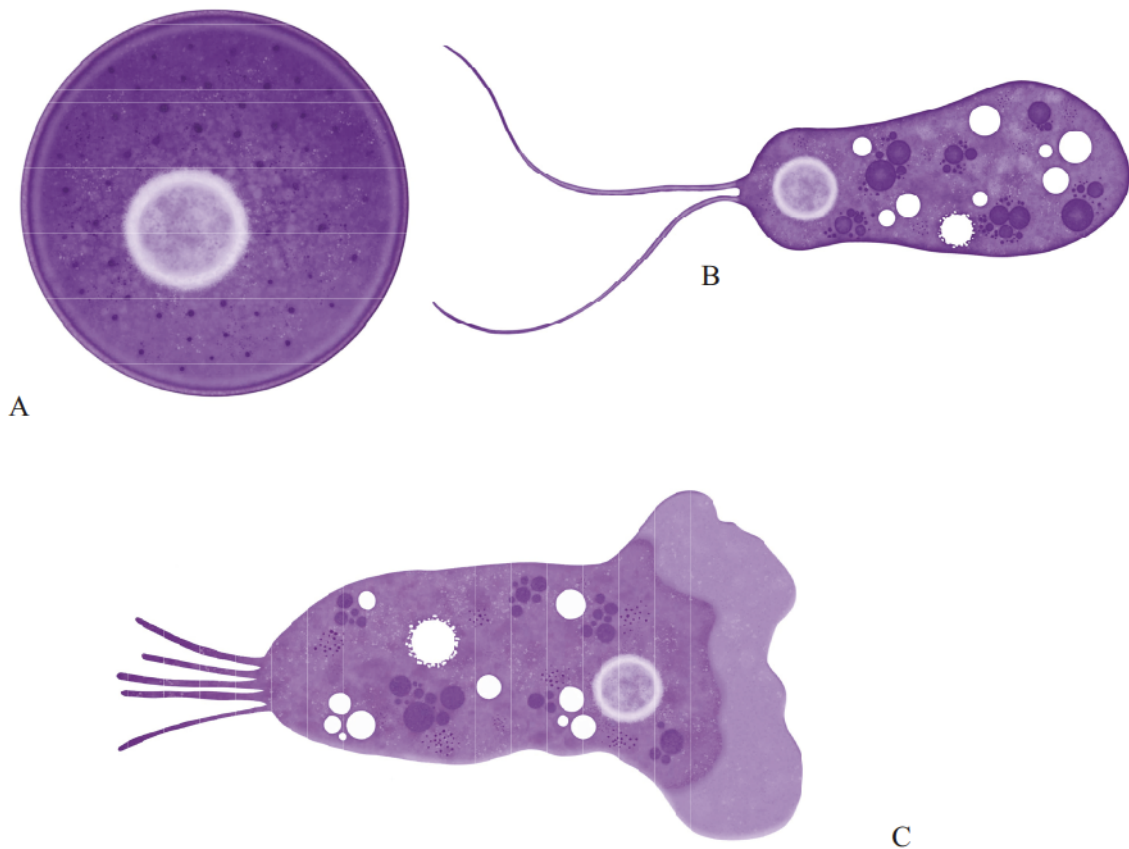


Figure 2. Three stages of *N. fowleri*: cyst (A), ameboid trophozoite (B) and flagellate trophozoite (C). (drawn by Oskar Szymański)

trophozoites (B) and flagellated forms (C). Cyst form can survive low temperatures during the winter. Temporary trophozoites can turn into non-feeding flagellated forms, which can transform back to the trophozoite stage [37].

Trophozoites enter the body through the nasal cavity while underwater. There have been described cases of infection through inhalation of dust containing cysts [35]. After entering the body, the amoeba travels using the olfactory nerves to reach the olfactory bulbs. After passing the cribriform plate it starts to multiply and feed on brain matter causing cerebral edema and herniation.

Amoebae of *Naegleria* genus (not the *N. fowleri*) have been discovered in the UK soli in 1972 [38]. A study from 2010 has shown *Naegleria* species in fish farms in South Western Germany also affecting trout [39]. According to a study from 2023 *Naegleria* species have been found in Swiss aquaculture causing Nodular Gill Disease in trout [40].

In the first half of the 1960s in Czech Republic 16 young people died because of PAM. Initially it

was supposed that the cause of the infection was bacteria, but 2 years after the outbreak *Naegleria* was identified [41]. The first cases of PAM in Great Britain were 3 children in 1970. One 2 year old boy died, two kids survived after enduring a mild meningitis treated with amphotericin [42].

#### *Symptoms and pathogenesis*

Most often cases of PAM include immunocompetent children and young adults. First symptoms might occur as early as 24 h after infection but usually range from 3 to 7 days. Symptoms are non-specific, typical for meningitis: headaches, fever, nausea, fatigue, and vomiting [43]. At a later stage the symptoms become more severe: anorexia, irritation, nuchal rigidity, Kernig's sign, Brudzinski's signs, lethargy, photophobia, confusion, seizures, and possible coma [44].

*Naegleria fowleri* uses pore forming proteins to kill cells and destroy the membranes of the host. The amoeba secretes lipases causing neuron demyelination of the white matter. It is capable of producing nitric oxide (NO) using an isoform of

nitric oxide synthase (NOS) while being resistant to toxic concentration of NO [45]. It has a HSP70 protein responsible for its resistance to inflammatory reactions of the host. The tissue damage after infection is also related to the immunologic response of eosinophils and neutrophils [46]. *N. fowleri* also produces strongly induced generation of intracellular reactive oxygen species (ROS) and cause cell death. Song et al. [47] suggested that *N. fowleri* induces ROS-dependent necroptosis in Jurkat T cells. Eosinophil mechanism proven ineffective against the amoeba. Neutrophils with the support of IgA, IgG and TNF- $\alpha$  are effective but cause a lot of damage to surrounding tissues [48].

#### Diagnosis

In *post-mortem* examination of a patient with *Naegleria* infection, changes of central nervous system such as soft, edematous, swollen and congested cerebral hemisphere can be found [37]. Therefore imaging diagnosis of central nervous system can be very helpful. Diagnosis of *N. fowleri* can be made by imaging: Computed tomography with contrast and magnetic resonance imaging reveal cerebral edema, cortical sulcal effacement, and cisternal obliteration around the midbrain and the subarachnoid space. In later stages of the disease scans may show necrotic areas, stenosis, and aneurysms [49]. Difficulty in diagnosis and perfusion of medicine through the BBB was shown in 1965 when the first case in Australia was reported [43].

Lumbar puncture can show polymorphonuclear leukocytes and *N. fowleri* trophozoites in the CSF. To reveal the amoeba Giemsa-Wright or trichrome staining is needed, Gram staining has proven not effective [37]. Diagnosis using the CSF can also be performed through microscopy, immunofluorescence assay (IF), enzyme-linked immunosorbent assay (ELISA) or flow cytometry (FC) [32]. To determine the genus and species of amoeba RT-PCR is recommended [49]. During the *Naegleria* infection CSF pressure usually increases to 600 mmH<sub>2</sub>O, which has been proven to be a direct indication of the patient's profound risk of death [37]. CSF's color may vary from greyish to yellowish-white in early stages, later it may turn red because of RBCs presence [44].

#### Treatment

There are no clinical trials for one treatment because *N. fowleri* infections are very rare in

humans. Most of the information regarding medication efficacy is based on case reports and researcher's *in vitro* studies.

According to Güémez and García [37] the most often used drugs include: amphotericin B combined with fluconazole, azithromycin, and rifampin. This combination (most effective in early stages of infection) is administered intravenously in high concentration or intrathecally due to poor BBB penetration.

It is important to take into consideration that Amphotericin B might cause significant side effects such as renal toxicity, anemia, chills, nausea, fever, vomiting, and headaches. The risk of these toxic effects may be lowered by conjugating Amphotericin B with silver nanoparticles. Even though Azithromycin is used in routine treatment other macrolides (e.g. Clarithromycin, Erythromycin) seem to be ineffective.

Prophylaxis includes chlorinating and/or boiling water used in houses and medical procedures, avoiding water activities during summer months, using nose plugs in water, frequent monitoring of bodies of water, posting warnings if the amoebae are present and implementing awareness campaigns.

#### *Trypanosoma cruzi*

##### Characteristic

*Trypanosoma cruzi* is a flagellate protozoan with life cycle between hematophagous insects of the Triatominae subfamily and various mammal species including human [50]. There are 3 forms of *T. cruzi*: epimastigote, amastigote and trypomastigote (Fig. 3). The vectors (Hemiptera, Reduviidae, Triatominae) excrete faeces or urine with trypomastigotes that enter the mammal's body for example through oral or nasal mucous membranes or the conjunctiva [51]. The vectors are present in rural regions of south American countries but deforestation led it out into the urban and suburban areas. *Trypanosoma cruzi* causes the Chagas disease (CD, American trypanosomiasis) [52].

Chagas disease used to be endemic in both Central and South America but due to human migration it has become a problem for both Europe and North America [53]. The spread of the disease may be caused by animals becoming infected and serve as reservoirs [54]. According to Hemmige et al. [52] about 8 million to 16–18 million people worldwide have already been infected with *T. cruzi*, and cases of chronic reactivation and congenital

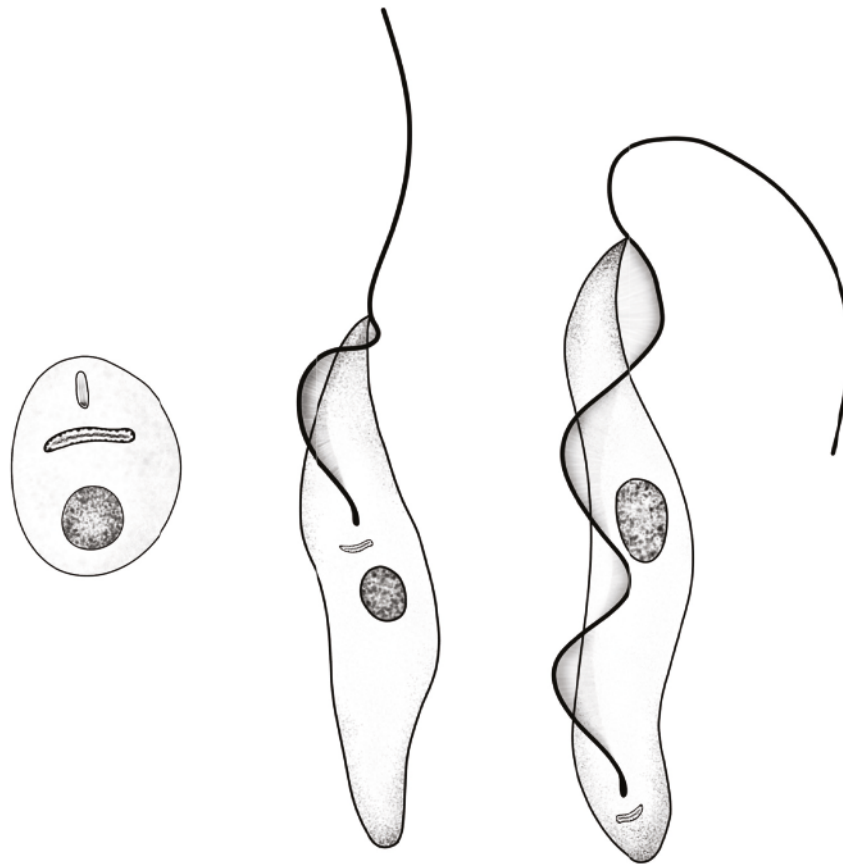


Figure 3. Morphologic forms of *Trypanosoma cruzi* (from left to right): amastigote, epimastigote and trypomastigote (drawn by Oskar Szymański)

Chagas disease will be present for years. WHO indicated in 2021 that around 56.000 new cases are diagnosed each year, and 12.000 patients die because of it annually [53]. Some authors predict that rising temperatures and changes in precipitation will affect the distribution, abundance, and behavior of vectors and their hosts, leading to changes in the incidence of infectious diseases [55,56]. Higher temperatures may accelerate vector life cycles, increase their reproductive rate, and increase the efficiency of pathogen transmission [57,58].

The transmission is possible not only through vectors, but also by organ transplants, blood transfusions, congenital infection, ingestion of food and beverages contaminated by triatomine insects and their faeces or secretions from the anal glands of local mammals (marsupials). The infection may also reignite after compromisation of the immune system [59].

Epimastigote and amastigote can divide, amastigote and trypomastigote can initiate infections. Recent studies show evidence of a transitional form of epimastigote (it appears when the epimastigote form transforms into trypomastigote) which can be

infective [60]. *Trypanosoma cruzi* attack human fibroblasts, macrophages and epithelial cells. [61]. The parasite uses many different receptors to invade new cells, for example TGF and EGF receptors, TLRs and even LDLr's (local increase in lipids might

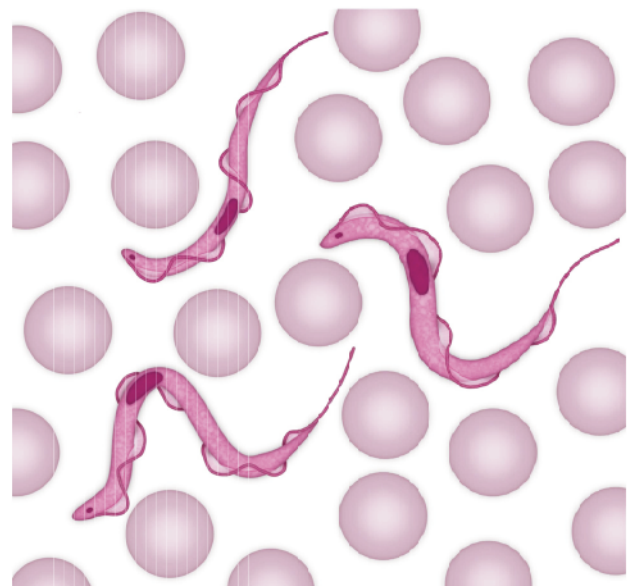


Figure 4. *Trypanosoma cruzi* trypomastigotes in blood (drawn by Oskar Szymański)

indicate an infection site) [62]. The vector takes up mostly trypomastigotes in peripheral blood of the mammalian host (Fig. 4) and up to 10% amastigotes [63].

#### *Symptoms and pathogenesis*

*Trypanosoma cruzi* causes Chagas disease which can be divided into an acute phase and a chronic phase [53]. Acute phase might be asymptomatic but if symptoms appear they include fever, inflammation at the inoculation site (chancres), unilateral palpebral oedema (Romaña sign), lymphadenopathy and hepatosplenomegaly. Some cases develop severe acute infection with symptoms including acute myocarditis, pericardial effusion, and meningoencephalitis which may even be lethal [64]. Acute stage may cause non-specific symptoms such as fever, chills, vomiting, rash, diarrhea, hepatosplenomegaly, anemia, thrombocytopenia, elevated liver enzymes [65]. Children under 5 years of age, immunocompromised adults and the elderly might develop a severe acute phase which is characterized by fulminant myocarditis which may lead to congestive heart failure and even death [53]. Red inflamed swollen area at the site of inoculation is called chagoma, a biopsy of this anomaly may show amastigotes and lymphocytes [52].

Acute phase turns into chronic phase which is usually asymptomatic and lasts until the disease is treated. Moreover, up to 40% of chronically ill patients may develop cardiomyopathy or

megaviscerata several years after the acute stage [66] and this stage might cause a continuous infection for over 20 years [61]. The chronic phase is characterized by amastigotes (Fig. 5) coexisting with host cells leading to long-lasting low-grade inflammation leading to chronic myocarditis and through that to fibrosis and cardiac remodeling [67].

The species is characterized by many strains which differ in virulence, pathogenicity, drug response and other traits. Due to specific glycoproteins on the surface, trypomastigotes are resistant to the complement system, while epimastigotes are sensitive to the alternative route of complement activation [68].

After the symptoms have subsided (after a few months), the patient enters the indeterminate stage. It is characterized by the presence of specific antibodies with lack of clinical manifestations. ECG and imaging of both the heart and the gastrointestinal system show no abnormalities [52].

Gastrointestinal disorders in Chagas disease include enlarged esophagus and/or colon caused by damage to intramural neurons. Esophageal symptoms as asymptomatic motility disorder with mild achalasia, in severe cases: megaesophagus, dysphagia, odynophagia, chest pain, weight loss, esophageal reflux. Colonic disorder might transform into megacolon with chronic constipation leading to fecaloma, volvulus [69].

If a patient in the chronic or indeterminate stage becomes immunocompromised, they may

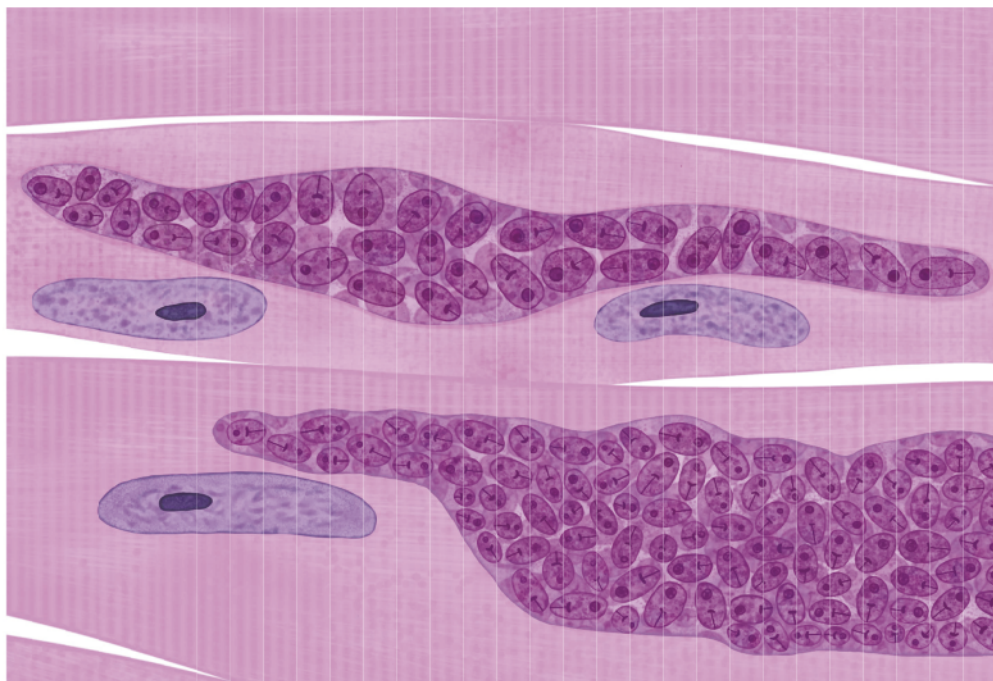


Figure 5. *Trypanosoma cruzi* amastigotes in pseudocysts in cardiac muscle (drawn by Oskar Szymański)

Table 1. Chagas cardiomyopathy – structural changes to the heart and arrhythmic manifestations [53,67]

Structural changes	Arrhythmic manifestations
Diffuse myocarditis with focal fibrosis (apex, posterior & inferior walls)	Premature ventricular contractions (PVCs) – monomorphic or polymorphic
Left ventricular hypertrophy	Right bundle branch block (RBBB) – in up to 28.8% of patients
Left ventricular apical aneurysms	Left anterior fascicular block (LAFB)
Dilated cardiomyopathy	Complete atrioventricular (AV) block (may show cannon A waves)
Thrombus formation in heart chambers (especially apical thrombi)	Atrial fibrillation – up to 5.4%
Myocyte degeneration and/or necrosis (e.g. hyaline degeneration)	Atrial flutter
Capillary endothelial cell damage	Bradycardia due to sinus node dysfunction
Chronic inflammation and progressive myocarditis	Sustained and non-sustained ventricular tachycardia (NSVT, VT)
Cardiomegaly	Ventricular fibrillation
Segmental myocardial damage and interstitial collagen accumulation	Irregular heart rhythm
Disruption of cardiac conduction system	Splitting of the second heart sound
Inferolateral left ventricular region – common site for ventricular arrhythmias	Sudden cardiac death (often due to VT or VF)
Parasite persistence leading to chronic myocardial injury	Electrical alternans
Microvascular abnormalities: perivascular inflammation, ischemia, reparative fibrosis	Low QRS voltage on ECG
Apical aneurysm (risk for stroke, thromboembolism)	Increased mortality with NSVT + LV systolic dysfunction (15.1-fold increase in death risk)

experience reactivation of the disease. The typical clinical manifestations of this occurrence are similar to the ones in the chronic and acute stages of the disease. One of the most common are skin lesions (whose biopsies contain intracellular amastigotes) and fever. But pathologies in the cardiovascular and gastrointestinal systems may also appear [70].

### Diagnosis

Laboratory diagnoses are usually gained through inspections of the CSF or blood. Effective methods include PCR, ELISA and IFA. Also, examination of tissue in immunocompromised patients may prove helpful [52]. In acute phase parasites are present in thick blood smears or thin smears with special stains, if the parasitemia is low laboratories use the Strout method, other methods like PCR or microscopic examination of cord blood (when congenital Chagas disease is suspected). Suspected

congenital CD should be retested after 6–9 months if initial tests' results are negative [53]. In indeterminate phase serological and parasitological evidence of infection, no changes in ECG or chest X-ray. In chronic phase: tests identifying specific antibodies (immunofluorescence, ELISA, indirect hemagglutination). Arrhythmias in cardiomyopathic patients can be easily identified in ECG. If ventricular arrhythmias occur a Holter monitoring is advised to detect arrhythmias not observed on a typical ECG. Chest X-ray can be a useful tool in the more advanced stages of the disease. Cardiomegaly of either chambers can be observed, but pulmonary congestion is a rather rare finding [67].

### Treatment

There is no vaccine for Chagas disease. Prophylactic measures are focused on lowering the risk of transmission from the vector. They include

care for the local infrastructure, educating local populus and serologic screening of donated blood [53,67].

The most common drugs used in treatment CD are benznidazole and nifurtimox: 60-day monotherapy course, 65–80% cure rate in the acute and indeterminate stages (higher in congenital CD) [61,62]. Both drugs are ineffective in the advanced chronic symptomatic phase. Contraindications to the use of these medications include pregnancy and renal/hepatic insufficiency. In patients with CD complete blood count, hepatic function profile, and serum chemistries, initially, after 4–6 weeks of treatment, and upon completion should be done. The patient's weight and the presence or absence of peripheral neuropathy should be noted every two weeks [71]. Prophylactic antitrypanosomal treatment in heart transplants is not recommended. Cardiac resynchronization therapy is under study for treating arrhythmias caused by CD [72]. In indeterminate and chronic phase antiparasitic treatment seems to be ineffective but recommended for women in reproductive age as prophylaxis against vertical transmission [73].

Heart transplant is also a way of treatment with survival rate at 1 year and 10 years better than in patients with different cardiomyopathies. Due to immunosuppression, there is a risk of reactivation which should be treated with benznidazole [67].

### ***Strongyloides stercoralis***

#### *Characteristic*

Strongyloidiasis, caused by the parasite *Strongyloides stercoralis*, is a neglected tropical disease (NTD). *Strongyloides stercoralis* was first described in 1876 [74]. Strongyloidiasis is most common in sub-Saharan Africa, South America, and South-east Asia, where prevalence may exceed 20%. Due to human migration, it has been encountered in the south parts of Europe and eastern US. [75]. Human infections in Europe reveal the presence of the parasite in Spain, Italy, France, Slovakia, and Romania [76]. *Strongyloides stercoralis* is physiologically better adapted for warmer climates than other *Strongyloides* species which may increase the transmission of this parasitic nematode in tropical and subtropical climates. [77].

Infection starts when the host walks barefoot on soil contaminated with filariform larvae that penetrate the skin and travel to the lungs through the circulatory system. They are then expectorated into the pharynx and swallowed. The larvae transform

into adult females inside the host's small intestine. Females produce rhabditiform larvae, which are excreted in stool. The larvae transform into male and female adult free-living forms (Fig. 6). They reproduce sexually in the soil leading to a new generation of filariform larvae. Rhabditiform larvae can also directly transform into filariform larvae in the soil [78]. The parasite can be transmitted through sexual oro-anal contact, most commonly seen in homosexual men [79]. There are reports of transmission through organ donation [80]. Fecal-oral route and through contaminated food or water can also be possible [75,81,82]. A study from 2024 investigates feline strongyloidiasis as a possible reservoir of infection to humans but the results were inconclusive [83]. A high predisposition to *S. stercoralis* infection has been associated with poor hygiene, malnutrition, excessive alcohol consumption, which lead to a weakened immune response, as well as with an increase in the level of endogenous corticosteroids [84, 85].

*Strongyloides stercoralis* is a parasite frequently forgotten, that affects about 613.9 million people and it is associated with a high mortality rate in kidney transplant recipients [86]. The difficult diagnosis and irregular excretion of larvae lead to an underreporting of infection rates. Information on infection rates is missing in many countries.

#### *Symptoms and pathogenesis*

Migrating larvae may cause respiratory symptoms such as dry cough and wheezing. Fever, dyspnoea, wheeze, pulmonary infiltrates on chest radiographs, and accompanying blood eosinophilia – all characteristics of Loeffler's-like syndrome may appear as well, but are rather rare [87,88]. Less common manifestations of chronic infection include reactive arthritis, chronic malabsorption, nephrotic syndrome, duodenal obstruction and hepatic lesions [89].

The gastrointestinal (GI) symptoms begin about two weeks post-infection. Penetration of the GI wall may lead to epigastric pain and tenderness worsened by eating, nausea, vomiting, diarrhea, constipation and weight loss [90,91].

Strongyloidiasis may lead to asthma. Patients who live in the endemic regions of this parasite with chronic obstructive pulmonary disease (COPD) or asthma should be regularly screened. It is of most importance when the patient is going to be treated with steroids because there is a risk of hyperinfection [92].



Figure 6. Rhabditiform larvae (A), filariform larvae (B), free-living adults: male (C) and female (D) of *S. stercoralis* (drawn by Oskar Szymański)

Strongyloidiasis may be asymptomatic (over 60%) with peripheral blood eosinophilia as the only indication. In chronic infection the larvae can migrate intradermally at the speed of 5–15 cm an hour resulting in itchy red tracts usually found in the perianal area and the upper thighs. It's known as larva currens and is pathognomonic for strongyloidiasis [93].

Untreated, chronic infection may lead to repeated mild pneumonitis with fever or restrictive pulmonary disease. Pulmonary manifestations of strongyloidiasis include: transient pulmonary opacities with cough, dyspnea, and bronchospasm often with associated pulmonary infection and peripheral eosinophilia [81].

Immunosuppression in infected patients can lead to hyperinfection. If the transformation from rhabditiform larva into filariform larva proceeds inside the host's gastrointestinal tract autoinfection is possible. In that case - filariform larvae penetrate the walls of the intestines and use the circulatory system to enter the lungs [94]. This process leads to chronic infection that can last up to 75 years [95].

#### *Hyperinfection*

*Strongyloides* hyperinfection appears in 2 types of patients: patients with chronic Strongyloidiasis who become immunosuppressed and immunocompromised patients who become infected by *Strongyloides* and enter the acute stage. There have

also been reports of patients who developed hyperinfection syndrome despite not being immunocompromised e.g. after laparoscopic surgery and in patients with gastric hypofunction [81,82].

Risk factors for hyperinfection are corticosteroid therapy, steroid sparing immunosuppressants and chemotherapeutics, both solid organ and bone marrow transplantation. HTLV-1 infection may lead to difficulties in treatment of the chronic stage but also to hyperinfection syndrome. HIV infection has not yet been found to cause hyperinfection syndrome, but it leads to higher prevalence of the disease [75,81,82].

In the beginning of hyperinfection symptoms include haemoptysis and wheezing. In chest imaging oedema, haemorrhage and pneumonitis are noted. Gastrointestinal disturbance which may progress to ileus bleeding. Septicaemia and multiorgan failure secondary to translocated gut flora may follow, along with Gram negative meningitis due to bacterial invasion of the cerebrospinal fluid [75,81,82].

Disseminated infection indicates the migration of the larvae away from the normal cycle path inside a host, in any organ or system, such as the central nervous system, lymph nodes, heart, pancreas, kidneys, ovaries, and skeletal muscles [96].

As the larvae perforate the gastrointestinal tract they can lead to migration of intestinal bacteria which may cause sepsis. The disseminated forms can produce symptoms similar to septic shock or another infection making it difficult to distinguish in the absence of adequate diagnostic suspicion [97].

Disseminated strongyloidiasis is often fatal, because of its rapid evolution and late diagnoses. Untreated hyperinfection can lead to death, with mortality rate at 85–100% [98].

### Diagnosis

Serology is more effective in strongyloidiasis diagnostics than stool microscopy. Coprodiagnostic procedures have low sensitivity (12.9–68.9%) while serological diagnostic procedures – much higher (68.0–98.2%) [99]. To increase diagnostic sensitivity, more than one stool sample should be examined from the same patient over consecutive days. One-day examination could give false negative result [99]. Low sensitivity of microscopic examination may be related to intermittent larval excretion and low infectious burden. Baermann technique and modified agar

plate method, can be used to improve the sensitivity [100].

Indirect method to diagnose strongyloidiasis is ELISA to IgG against filariform larvae. The sensitivity is 83–89% and specificity of 97.2%. There are several commercially available serologic tests for strongyloidiasis [101].

As strongyloidiasis is usually asymptomatic the most common cause of further diagnostic investigation is eosinophilia. As it may be caused by multiple other disorders it is important to confirm with a second test and consider the patient's history. This might help in ruling out all the other possibilities. If the patient has recently returned from a region where strongyloidiasis is endemic – 3 stool samples should be collected and investigated through microscopy. Also, a blood serology test for *S. strongyloides* is recommended [75,81,82,102, 103].

### Treatment

The most successful treatment is orally administered ivermectin (IVM) that does not cross the BBB so it is not likely to cause paralysis to the patient. A single dose of IVM (200 µg/kg) was shown to be effective in uncomplicated chronic strongyloidiasis [104]. Some authors recommend using a double dose on subsequent days or two weeks apart [75,81,82]. Other authors point that multiple doses of IVM do not show higher efficacy and are tolerated less than a single dose [105]. Albendazole and thiabendazole can be used in treatment but ivermectin was proven to be more effective. Albendazole (400 mg orally twice a day) can be used to support treatment with ivermectin. Repeated serological testing after treatment seems to be the best way to test for cure [75].

A patient with proven strongyloidiasis should be referred to an infectious disease specialist because the treatment might be difficult to obtain outside a hospital. If a patient suffers from a coinfection of both *S. stercoralis* and *Loa loa*, ivermectin treatment may lead to a higher risk of encephalopathy [75,81].

Climate change, especially rising temperatures, may favour the spread of diseases for example transmitted by vectors. Parasites can quickly adapt to a changing world. For our common safety, healthcare workers should be aware of these threats so they can effectively combat parasitic diseases, whose range is constantly evolving.

## References

- [1] Phan I.Q., Rice C.A., Craig J., Noorai R.E., McDonald J.R., Subramanian S., Tillery L., Barrett L.K., Shankar V., Morris J.C., Van Voorhis W.C., Kyle D.E., Myler P. J. 2021. The transcriptome of *Balamuthia mandrillaris* trophozoites for structure-guided drug design. *Scientific Reports* 11(1): 21664. doi:10.1038/s41598-021-99903-8
- [2] Bronstein A.M., Lukashev A.N., Maximova M.S., Sacharova T.V. 2021. The autochthonous cases of acute strongyloidiasis in the Moscow region. *Germs* 11(1): 116–119. doi:10.18683/germs.2021.1248
- [3] Forsyth C., Agudelo Higuaita N.I., Hamer S.A., Ibarra-Cerdeñ C.N., Valdez-Tah A., Stigler Granados P., Hamer G.L., Vingiello M., Beatty N.L. 2024. Climate change and *Trypanosoma cruzi* transmission in North and central America. *The Lancet. Microbe* 5(10): 100946. doi:10.1016/j.lanmic.2024.07.009
- [4] Schuster F.L., Visvesvara G.S. 2004. Free-living amoebae as opportunistic and non-opportunistic pathogens of humans and animals. *International Journal for Parasitology* 34: 1001–1027.
- [5] Lorenzo-Morales J., Cabello-Vílchez A.M., Martín-Navarro C.M., Martínez-Carretero E., Piñero J.E., Valladares B. 2013. Is *Balamuthia mandrillaris* a public health concern worldwide? *Trends in Parasitology* 29(10): 483–488. doi:10.1016/j.pt.2013.07.009
- [6] Wang L., Cheng W., Li B., Jian Z., Qi X., Sun D., Gao J., Lu X., Yang Y., Lin K., Lu C., Chen J., Li C., Wang G., Gao T. 2020. *Balamuthia mandrillaris* infection in China: A retrospective report of 28 cases. *Emerging Microbes and Infections* 9(1): 2348–2357. doi:10.1080/22221751.2020.1835447
- [7] Rodríguez-Expósito R.L., Carbonell L., Recuero-Gil J., Martínez J., Martínez-Valverde R., Martínez-Fernandez C., Ortega-Porcel J., Hernández A.B., Corpa J.M., Cortijo E.M., Sánchez-Nicolás J., Moya S., Pérez-Pérez P., Reyes-Batlle M., Domínguez-de-Barros A., García-Pérez O., Magnet A., Izquierdo F., Fenoy S., Del Águila C., Lorenzo-Morales J. 2025. Fatal amoebic meningoencephalitis caused by *Balamuthia mandrillaris* in *Pongo pygmaeus* and first case report in *Pan troglodytes verus*. *Frontiers in Veterinary Science* 12: 1534378. doi:10.3389/fvets.2025.1534378
- [8] Matin A., Siddiqui R., Jayasekera S., Khan N.A. 2008. Increasing importance of *Balamuthia mandrillaris*. *Clinical Microbiology Reviews* 21(3): 435–448. doi:10.1128/CMR.00056-07
- [9] Javed Z., Hussain M.M., Ghanchi N., Gilani A., Enam S.A. 2024. Non-granulomatous meningoencephalitis with *Balamuthia mandrillaris* mimicking a tumor: first confirmed case from Pakistan. *Surgical Neurology International*: 15: 238. doi:10.25259/SNI\_181\_2024
- [10] Bhosale N.K., Parija S.C. 2021. *Balamuthia mandrillaris*: An opportunistic, free-living amoeba – an updated review. *Tropical Parasitology* 11(2): 78–88. doi:10.4103/tp.tp\_36\_21
- [11] Balczun C., Scheid P.L. 2016. Detection of *Balamuthia mandrillaris* DNA in the storage case of contact lenses in Germany. *Parasitology Research* 115(5): 2111–2114. doi:10.1007/s00436-016-4979-4
- [12] Mbaeyi C. 2010. Transplant-transmitted *Balamuthia mandrillaris* – Arizona, 2010. Morbidity and Mortality Weekly Report 59(36): 1182. <https://www.cdc.gov/mmwr/preview/mmwrhtml/mm5936a4.htm>
- [13] Schlessinger S., Kokko K., Fratkin J., Butt F., Hawxby A., Todaro M. 2010. *Balamuthia mandrillaris* transmitted through organ transplantation – Mississippi, 2009. Morbidity and Mortality Weekly Report 59(36): 1165–1170. CDC. [https://www.amjtransplant.org/article/S1600-6135\(22\)27793-4/pdf](https://www.amjtransplant.org/article/S1600-6135(22)27793-4/pdf)
- [14] Basavaraju S.V., Kuehnert M.J., Zaki S.R., Sejvar J.J. 2014. Encephalitis caused by pathogens transmitted through organ transplants, United States, 2002–2013. *Emerging Infectious Diseases* 20(9): 1443–1451. doi:10.3201/eid2009.131332
- [15] Cope J.R., Landa J., Nethercut H., Collier S.A., Glaser C., Moser M., Puttagunta R., Yoder J.S., Ali I.K., Roy S.I. 2019. The epidemiology and clinical features of *Balamuthia mandrillaris* disease in the United States, 1974–2016. *Clinical Infectious Diseases* 68(11): 1815–1822. doi:10.1093/cid/ciy813
- [16] Visvesvara G.S., Martinez A.J., Schuster F.L., Leitch G.J., Wallace S.V., Sawyer T.K., Anderson M. 1990. Leptomyxid ameba, a new agent of amebic meningoencephalitis in humans and animals. *Journal of Clinical Microbiology* 28(12): 2750–2756. doi:10.1128/jcm.28.12.2750-2756.1990
- [17] Kodet R., Nohýnková E., Tichý M., Soukup J., Visvesvara G.S. 1998. Amebic encephalitis caused by *Balamuthia mandrillaris* in a Czech child: description of the first case from Europe. *Pathology, Research and Practice* 194(6): 423–429. doi:10.1016/S0344-0338(98)80033-2
- [18] Rowen J.L., Doerr C.A., Vogel H., Baker C.J. 1995. *Balamuthia mandrillaris*: a newly recognized agent for amebic meningoencephalitis. *The Pediatric Infectious Disease Journal* 14(8): 705–710.
- [19] Yu X., Xu W. 2025. A case report of *Balamuthia mandrillaris* encephalitis: experience from Central China. *Neurosurgical Subspecialties* 1(1): 44–47. doi:10.14218/NSSS.2025.00001
- [20] Gianinazzi C., Schild M., Zumkehr B., Wüthrich F., Nüesch I., Ryter R., Schürch N., Gottstein B., Müller N. 2010. Screening of Swiss hot spring resorts for potentially pathogenic free-living amoebae. *Experimental Parasitology* 126(1): 45–53. doi:10.1016/j.exppara.2009.12.008

- [21] van der Beek N.A., van Tienen C., de Haan J.E., Roelfsema J., Wismans P.J., van Genderen P.J., Tanghe H.L., Verdijk R.M., Titulaer M.J., van Hellemond J.J. 2015. Fatal *Balamuthia mandrillaris* Meningoencephalitis in the Netherlands after travel to the Gambia. *Emerging Infectious Diseases* 21(5): 896–898. doi:10.3201/eid2105.141325
- [22] Visvesvara G.S., Moura H., Schuster F.L. 2007. Pathogenic and opportunistic free-living amoebae: *Acanthamoeba* spp., *Balamuthia mandrillaris*, *Naegleria fowleri*, and *Sappinia diploidea*. *FEMS Immunology and Medical Microbiology* 50(1): 1–26. doi:10.1111/j.1574-695x.2007.00232.x
- [23] Krasaelap A., Prechawit S., Chansaenroj J., Punyahotra P., Puthanakit T., Chomtho K., Shuangshoti S., Amornfa J., Poovorawan Y. 2013. Fatal *Balamuthia* amoebic encephalitis in a healthy child: a case report with review of survival cases. *Korean Journal of Parasitology* 51(3): 335–341. doi:10.3347/kjp.2013.51.3.335
- [24] Li Z., Li W., Li Y., Ma F., Li G. 2024. A case report of *Balamuthia mandrillaris* encephalitis. *Heliyon* 10(5): e26905. doi:10.1016/j.heliyon.2024.e26905
- [25] Huang Z.H., Ferrante A., Carter R.F. 1999. Serum antibodies to *Balamuthia mandrillaris*, a free-living amoeba recently demonstrated to cause granulomatous amoebic encephalitis. *Journal of Infectious Diseases* 179(5): 1305–1308. doi:10.1086/314731
- [26] Schuster F.L., Yagi S., Wilkins P.P., Gavali S., Visvesvara G.S., Glaser C.A. 2008. *Balamuthia mandrillaris*, agent of amoebic encephalitis: detection of serum antibodies and antigenic similarity of isolates by enzyme immunoassay. *Journal of Eukaryotic Microbiology* 55(4): 313–320. doi:10.1111/j.1550-7408.2008.00333.x
- [27] Kiderlen A.F., Radam E., Tata P.S. 2009. Assessment of *Balamuthia mandrillaris*-specific serum antibody concentrations by flow cytometry. *Parasitology Research* 104(3): 663–670. doi:10.1007/s00436-008-1243-6
- [28] Combs F.J. Jr., Erly W.K., Valentino C.M., Rance N.E. 2011. Best cases from the AFIP: *Balamuthia mandrillaris* amoebic meningoencephalitis. *Radiographics: a review publication of the Radiological Society of North America, Inc* 31(1): 31–35. doi:10.1148/rg.311105067
- [29] Bravo F.G., Alvarez P.J., Gotuzzo E. 2011. *Balamuthia mandrillaris* infection of the skin and central nervous system: an emerging disease of concern to many specialties in medicine. *Current Opinion in Infectious Diseases* 24(2): 112–117. doi:10.1097/QCO.0b013e3283428d1e
- [30] Mungroo M.R., Shahbaz M.S., Anwar A., Saad S.M., Khan K.M., Khan N.A., Siddiqui R. 2020. Aryl quinazolinone derivatives as novel therapeutic agents against brain-eating amoebae. *ACS Chemical Neuroscience* 11(16): 2438–2449. doi:10.1021/acschemneuro.9b00596
- [31] Schuster F.L., Visvesvara G.S. 1996. Axenic growth and drug sensitivity studies of *Balamuthia mandrillaris*, an agent of amoebic meningoencephalitis in humans and other animals. *Journal of Clinical Microbiology* 34(2): 385–388. doi:10.1128/jcm.34.2.385-388.1996
- [32] Siddiqui R., Ali I.K.M., Cope J.R., Khan N.A. 2016. Biology and pathogenesis of *Naegleria fowleri*. *Acta Tropica* 164: 375–394. doi:10.1016/j.actatropica.2016.09.009
- [33] Heilmann A., Rueda Z., Alexander D., Laupland K.B., Keynan Y. 2024. Impact of climate change on amoeba and the bacteria they host. *Journal of the Association of Medical Microbiology and Infectious Disease Canada* 9(1): 1–5. doi:10.3138/jammi-2023-09-08
- [34] Kemble S.K., Lynfield R., DeVries A.S., Drehner D.M., Pomputius W.F., 3rd, Beach M.J., Visvesvara G.S., da Silva A.J., Hill V.R., Yoder J.S., Xiao L., Smith K.E., Danila R. 2012. Fatal *Naegleria fowleri* infection acquired in Minnesota: possible expanded range of a deadly thermophilic organism. *Clinical Infectious Diseases* 54(6): 805–809. doi:10.1093/cid/cir961
- [35] Maciver S.K., Piñero J.E., Lorenzo-Morales J. 2020. Is *Naegleria fowleri* an emerging parasite? *Trends in Parasitology* 36(1): 19–28. doi:10.1016/j.pt.2019.10.008
- [36] Dzikowiec M., Góralaska K., Błaszowska J. 2017. Neuroinvasions caused by parasites. *Annals of Parasitology* 63(4): 243–253. doi:10.17420/ap6304.111
- [37] Güémez A., García E. 2021. Primary amoebic meningoencephalitis by *Naegleria fowleri*: pathogenesis and treatments. *Biomolecules* 11: 1320. doi:10.3390/biom11091320
- [38] Das S.R. 1972. Isolation of *Naegleria* and *Hartmannella* amoebae from Beckenham (London) soils and their pathogenicity in mice. *Transactions of the Royal Society of Tropical Medicine and Hygiene* 66(4): 663–664. doi:10.1016/0035-9203(72)90313-6
- [39] Dyková I., Kostka M., Wortberg F., Nardy E., Pecková H. 2010. New data on aetiology of nodular gill disease in rainbow trout, *Oncorhynchus mykiss*. *Folia Parasitologica (Praha)*. 57(3): 157–163.
- [40] Vannetti S.M., Wynne J.W., English C., Huynh C., Knüsel R., de Sales-Ribeiro C., Widmer M., Delalay G., Schmidt-Posthaus H. 2023. Amoeba species colonizing the gills of rainbow trout (*Oncorhynchus mykiss*) in Swiss aquaculture. *Journal of Fish Diseases* 46(9): 987–999. doi:10.1111/jfd.13819
- [41] Kožíšek F., Rychlíková E., Pummann P. 2019. 16 victims and 16 years for elucidating the case. A reminder of the worst Czech bathing water epidemic

- in Ústí nad Labem, *Hygiena* 64(2): 52–58.  
doi:10.21101/hygiena.a1708
- [42] Apley J., Clarke S.K., Roome A.P., Sandry S.A., Saygi G., Silk B., Warhurst D.C. 1970. Primary amoebic meningoencephalitis in Britain. *British Medical Journal* 1(5696): 596–599.  
doi:10.1136/bmj.1.5696.596
- [43] Cope J.R., Ali I.K. 2016. Primary amoebic meningoencephalitis: what have we learned in the last 5 years?. *Current Infectious Disease Reports* 18(10): 31. doi:10.1007/s11908-016-0539-4
- [44] Grace E., Asbill S., Virga, K. 2015. *Naegleria fowleri*: pathogenesis, diagnosis, and treatment options. *Antimicrobial Agents and Chemotherapy* 59(11): 6677–6681. doi:10.1128/AAC.01293-15
- [45] Rojas-Hernández S., Rodríguez-Monroy M.A., Moreno-Fierros L., Jarillo-Luna A., Carrasco-Yépez M., Miliar-García A., Campos-Rodríguez R. 2007. Nitric oxide production and nitric oxide synthase immunoreactivity in *Naegleria fowleri*. *Parasitology Research* 101(2): 269–274.  
doi:10.1007/s00436-007-0495-x
- [46] Cervantes-Sandoval I., Serrano-Luna J.D.J., García-Latorre E., Tsutsumi V., Shibayama M. 2008. Characterization of brain inflammation during primary amoebic meningoencephalitis. *Parasitology International* 57(3): 307–313.  
doi:10.1016/j.parint.2008.01.006
- [47] Song K.J., Jang Y.S., Lee Y.A., Kim K.A., Lee S.K., Shin M.H. 2011. Reactive oxygen species-dependent necroptosis in Jurkat T cells induced by pathogenic free-living *Naegleria fowleri*. *Parasite Immunology* 33(7): 390–400.  
doi:10.1111/j.1365-3024.2011.01297.x
- [48] De Oca A.C., Carrasco-Yépez M., Campos-Rodríguez R., Pacheco-Yépez J., Bonilla-Lemus P., Pérez-López J., Rojas-Hernández S. 2016. Neutrophils extracellular traps damage *Naegleria fowleri* trophozoites opsonized with human IgG. *Parasite Immunology* 38(8): 481–495.  
doi:10.1111/pim.12337
- [49] Bellini N.K., Santos T.M., da Silva M.T.A., Thiemann O.H. 2018. The therapeutic strategies against *Naegleria fowleri*. *Experimental Parasitology* 187: 1–11.  
doi:10.1016/j.exppara.2018.02.010
- [50] De Fuentes-Vicente J.A., Vidal-López D.G., Flores-Villegas A.L., Moreno-Rodríguez A., De Alba-Alvarado M.C., Salazar-Schettino P.M., Rodríguez-López M.H., Gutiérrez-Cabrera A.E. 2019. *Trypanosoma cruzi*: a review of biological and methodological factors in Mexican strains. *Acta Tropica* 195: 51–57.  
doi:10.1016/j.actatropica.2019.04.024
- [51] Herrera L. 2014. *Trypanosoma cruzi*, the causal agent of Chagas disease: boundaries between wild and domestic cycles in Venezuela. *Frontiers in Public Health* 2: 259. doi:10.3389/fpubh.2014.00259
- [52] Hemmige V., Tanowitz H., Sethi A. 2012. *Trypanosoma cruzi* infection: a review with emphasis on cutaneous manifestations. *International Journal of Dermatology* 51(5): 501–508.  
doi:10.1111/j.1365-4632.2011.05380.x
- [53] Echavarría N.G., Echeverría L.E., Stewart M., Gallego C., Saldarriaga C. 2021. Chagas disease: chronic Chagas cardiomyopathy. *Current Problems in Cardiology* 46(3): 100507.  
doi:10.1016/j.cpcardiol.2019.100507
- [54] Machado F.S., Dutra W.O., Esper L., Gollob K.J., Teixeira M.M., Factor S.M., Weiss L. M., Nagajyothi F., Tanowitz H.B., & Garg N.J. 2012. Current understanding of immunity to *Trypanosoma cruzi* infection and pathogenesis of Chagas disease. *Seminars in Immunopathology* 34(6): 753–770.  
doi:10.1007/s00281-012-0351-7
- [55] Patz J.A., Githeko A.K., McCarty J.P., Hussein S., Confalonieri U. DeWet N. 2003. Climate change and infectious diseases. *Climate Change and Human Health: Risks and Responses* 2: 103–132.
- [56] Van de Vuurst P. Escobar L.E. 2023. Climate change and infectious disease: a review of evidence and research trends. *Infectious Diseases of Poverty* 12(1): 51. doi:10.1186/s40249-023-01102-2
- [57] Yadav N., Upadhyay R.K. 2023. Global effect of climate change on sea-seasonal cycles, vector population and rising challenges of communicable diseases: a review. *Journal of Atmospheric Science Research* 6(1): 21–59. doi:10.30564/jasr.v6i1.5165
- [58] Brasil L.S., Silvério D.V., Silva J.O.A., Santos W.S., de Melo L.V., Juen L., França F.M., Vieira T.B. 2025. Potential geographic displacement of Chagas disease vectors under climate change. *Medical and Veterinary Entomology* 39(4): 709–717. doi:10.1111/mve.12810
- [59] Shikanai-Yasuda M.A., Carvalho N.B. 2012. Oral transmission of Chagas disease. *Clinical Infectious Diseases* 54(6): 845–852. doi:10.1093/cid/cir956
- [60] De Souza W., Barrias E.S. 2020. May the epimastigote form of *Trypanosoma cruzi* be infective? *Acta Tropica* 212: 105688.  
doi:10.1016/j.actatropica.2020.105688
- [61] Jimenez V. 2014. Dealing with environmental challenges: mechanisms of adaptation in *Trypanosoma cruzi*. *Research in Microbiology* 165(3): 155–165. doi:10.1016/j.resmic.2014.01.006
- [62] Bern C., Kjos S., Yabsley M.J., Montgomery S.P. 2011. *Trypanosoma cruzi* and Chagas disease in the United States. *Clinical Microbiology Reviews* 24(4): 655–681. doi:10.1128/CMR.00005-11
- [63] Tyler K.M., Engman D.M. 2001. The life cycle of *Trypanosoma cruzi* revisited. *International Journal for Parasitology* 31(5–6): 472–481.  
doi:10.1016/s0020-7519(01)00153-9
- [64] Nunes M.C.P., Beaton A., Acquatella H., Bern C., Bolger A.F., Echeverría L.E., Dutra W.O., Gascon J.,

- Morillo C.A., Oliveira-Filho J., Ribeiro A.L.P., Marin-Neto J.A., American Heart Association Rheumatic Fever, Endocarditis and Kawasaki Disease Committee of the Council on Cardiovascular Disease in the Young; Council on Cardiovascular and Stroke Nursing; and Stroke Council. 2018. Chagas cardiomyopathy: an update of current clinical knowledge and management: a scientific statement from the American Heart Association. *Circulation* 138(12): e169–e209. doi:10.1161/CIR.0000000000000599
- [65] Añez N., Carrasco H., Parada H., Crisante G., Rojas A., Gonzalez N., Ramirez J.L., Guevara P., Rivero C., Borges R., Scorza J.V. 1999. Acute Chagas disease in western Venezuela: a clinical, seroparasitologic, and epidemiologic study. *The American Journal of Tropical Medicine and Hygiene* 60(2): 215–222. doi:10.4269/ajtmh.1999.60.215
- [66] Pérez-Molina J.A., Molina I. 2018. Chagas disease. *Lancet* (London, England) 391(10115): 82–94. doi:10.1016/S0140-6736(17)31612-4
- [67] Santos É., Menezes Falcão L. 2020. Chagas cardiomyopathy and heart failure: from epidemiology to treatment. *Revista Portuguesa de Cardiologia* 39(5): 279–289. doi:10.1016/j.repc.2019.12.006
- [68] Ramírez-Tolosa G., Ferreira A. 2017. *Trypanosoma cruzi* evades the complement system as an efficient strategy to survive in the mammalian host: the specific roles of host/parasite molecules and *Trypanosoma cruzi* calreticulin. *Frontiers in Microbiology* 1: 8: 1667. doi:10.3389/fmicb.2017.01667
- [69] da Silveira A.B., Lemos E.M., Adad S.J., Correa-Oliveira R., Furness J.B., D'Avila Reis D. 2007. Megacolon in Chagas disease: a study of inflammatory cells, enteric nerves, and glial cells. *Human Pathology* 38(8): 1256–1264. doi:10.1016/j.humpath.2007.01.020
- [70] Altclas J., Sinagra A., Jaimovich G., Salgueira C., Luna C., Requejo A., Milovic V., De Rissio A., Feldman L., Riart A. 1999. Reactivation of chronic Chagas disease following allogeneic bone marrow transplantation and successful pre-emptive therapy with benznidazole. *Transplant Infectious Disease* 1(2): 135–137. doi:10.1034/j.1399-3062.1999.010207.x
- [71] Bern C., Montgomery S.P., Herwaldt B.L., Rassi A., Marin-Neto J.A., Dantas, R.O., Maguire J. H., Acquatella H., Morillo C., Kirchhoff L.V., Gilman R.H., Reyes P.A., Salvatella R., Moore, A.C. 2007. Evaluation and treatment of chagas disease in the United States: a systematic review. *JAMA* 298(18): 2171–2181.
- [72] Araújo E.F., Chamlian E.G., Peroni A.P., Pereira W.L., Gandra S.M., Rivetti L.A. 2014. Cardiac resynchronization therapy in patients with chronic Chagas cardiomyopathy: long-term follow up. *Revista Brasileira de Cirurgia Cardiovascular* 29(1): 31–36. doi:10.5935/1678-9741.20140008
- [73] Cafferata M.L., Toscani M.A., Althabe F., Belizán J.M., Bergel E., Berrueta M., Capparelli E.V., Ciganda Á., Danesi E., Dumonteil E., Gibbons L., Gulayin P.E., Herrera C., Momper J.D., Rossi S., Shaffer J.G., Schijman A.G., Sosa-Estani S., Stella, C.B., Klein K., Buekens P. 2020. Short-course benznidazole treatment to reduce *Trypanosoma cruzi* parasitic load in women of reproductive age (BETTY): a non-inferiority randomized controlled trial study protocol. *Reproductive Health* 17(1): 128. doi:10.1186/s12978-020-00972-1
- [74] Sing A., Leitritz L., Bogner J.R., Heesemann J. 1999. First-glance diagnosis of *Strongyloides stercoralis* autoinfection by stool microscopy. *Journal of Clinical Microbiology* 37(5): 1610–1611. doi:10.1128/JCM.37.5.1610-1611.1999
- [75] Greaves D., Coggle S., Pollard C., Aliyu S.H., Moore E.M. 2013. *Strongyloides stercoralis* infection. *BMJ* 347: f4610. doi:10.1136/bmj.f4610
- [76] Ottino L., Buonfrate D., Paradies P., Bisoffi Z., Antonelli A., Rossolini G.M., Gabrielli S., Bartoloni A., Zammarchi L. 2020. Autochthonous human and canine *Strongyloides stercoralis* infection in Europe: report of a human case in an Italian teen and systematic review of the literature. *Pathogens* 9(6): 439. doi:10.3390/pathogens9060439
- [77] Gregory B.T., Desouky M., Slaughter J., Hallem E.A., Bryant A.S. 2024. Thermosensory behaviors of the free-living life stages of *Strongyloides* species support parasitism in tropical environments. *bioRxiv: the preprint server for biology* 2024.09.12.612595. doi:10.1101/2024.09.12.612595
- [78] Gordon C.A., Utzinger J., Muhi S., Becker S.L., Keiser J., Khieu V., Gray D.J. 2024. Strongyloidiasis. *Nature Reviews. Disease Primers* 10(1): 6. doi:10.1038/s41572-023-00490-x
- [79] Chessell C., Rabuszko L., Richardson D., Llewellyn C. 2024. Factors associated with the sexual transmission of *Strongyloides stercoralis* in men who have sex with men: a systematic review. *Journal of the European Academy of Dermatology and Venereology* 38(4): 673–679. doi:10.1111/jdv.19664
- [80] Centers for Disease Control and Prevention (CDC). 2012. Transmission of *Strongyloides stercoralis* through transplantation of solid organs – Pennsylvania. *Morbidity and Mortality Weekly Report* 62(14): 264–266. <https://www.cdc.gov/mmwr/preview/mmwrhtml/mm6214a2.htm>
- [81] Czeresnia J.M., Weiss L.M. 2022. *Strongyloides stercoralis*. *Lung* 200(2): 141–148. doi:10.1007/s00408-022-00528-z
- [82] Teixeira M.C., Pacheco F.T., Souza J.N., Silva M.L., Inês E.J., Soares N.M. 2016. *Strongyloides stercoralis* Infection in alcoholic patients. *BioMed Research*

- International* 4872473. doi:10.1155/2016/4872473
- [83] Zhao H., Bradbury R.S. 2024. Feline strongyloidiasis: an insight into its global prevalence and transmission cycle. *One Health* 19: 100842. doi:10.1016/j.onehlt.2024.100842
- [84] de Oliveira L.C., Ribeiro C.T., Mendes D., Oliveira T.C., Costa-Cruz J.M. 2002. Frequency of *Strongyloides stercoralis* infection in alcoholics. *Memorias do Instituto Oswaldo Cruz* 97(1): 119–121. doi:10.1590/s0074-02762002000100021
- [85] Yeh M.Y., Aggarwal S., Carrig M., Azeem A., Nguyen A., Devries S., Destache C., Nguyen T., Velagapudi M. 2023. *Strongyloides stercoralis* infection in humans: a narrative Review of the Mmst neglected parasitic disease. *Cureus* 15(10): e46908. doi:10.7759/cureus.46908
- [86] Abrantes R., Barata R., Caeiro F., Ferreira A., Nolasco F. 2023. *Strongyloides stercoralis* after renal transplantation – a global threat. *Nefrologia* 43(6): 789–790. doi:10.1016/j.nefro.2022.11.017
- [87] Singh B., Verma S., Rashid K., Stoltzfus M.T. 2024. Loeffler’s syndrome induced by the transmigration of *Strongyloides stercoralis* to the lungs: a case report and literature review. *Cureus* 16(12): e75897. doi:10.7759/cureus.75897
- [88] Bae K., Jeon K.N., Ha J.Y., Lee J.S., Na B.K. 2018. Pulmonary strongyloidiasis presenting micronodules on chest computed tomography. *Journal of Thoracic Disease* 10(8): E612–E615. doi:10.21037/jtd.2018.07.32
- [89] Mejia R., Nutman T.B. 2012. Screening, prevention, and treatment for hyperinfection syndrome and disseminated infections caused by *Strongyloides stercoralis*. *Current Opinion in Infectious Diseases* 25(4): 458–463. doi:10.1097/QCO.0b013e3283551dbd
- [90] Vadlamudi R.S., Chi D.S., Krishnaswamy G. 2006. Intestinal strongyloidiasis and hyperinfection syndrome. *Clinical and Molecular Allergy* 4: 8. doi:10.1186/1476-7961-4-8
- [91] Cai S., Zhou M., Zhang Y., Luo W., Xie B. 2024. Residual gastritis associated with *Strongyloides stercoralis* infection: a case report. *Medicine (Baltimore)* 103(39): e39714. doi:10.1097/MD.00000000000039714
- [92] Ashiri A., Rafiei A., Beiromvand M., Khanzadeh A., Alghasi A. 2021. Case report: challenges for the diagnosis and treatment of *Strongyloides stercoralis* in chronic obstructive pulmonary disease patients. *American Journal of Tropical Medicine and Hygiene* 106(2): 695–699. doi:10.4269/ajtmh.21-1011
- [93] Hamze H., Tai T., Harris D. 2023. *Strongyloides* hyperinfection syndrome precipitated by immunosuppressive therapy for rheumatoid arthritis and COVID-19 pneumonia. *Tropical Diseases, Travel Medicine and Vaccines* 9(1): 15. doi:10.1186/s40794-023-00201-0
- [94] Buonfrate D., Bradbury R.S., Watts M.R., Bisoffi Z. 2023. Human strongyloidiasis: complexities and pathways forward. *Clinical Microbiology Reviews* 36(4): e0003323. doi:10.1128/cmr.00033-23
- [95] Prendki V., Fenaux P., Durand R., Thellier M., Bouchaud O. 2011. Strongyloidiasis in man 75 years after initial exposure. *Emerging Infectious Diseases* 17(5): 931–932. doi:10.3201/eid1705.100490
- [96] Karanam L.S.K., Basavraj G.K., Papireddy C.K.R. 2021. *Strongyloides stercoralis* hyperinfection syndrome. *Indian Journal of Surgery* 83 (Suppl. 3): 582–586. doi:10.1007/s12262-020-02292-x
- [97] H Rodríguez-Guardado A., Álvarez-Martínez M.J., Flores M.D., Sulleiro E., Torrús-Tendero D., Velasco M., Membrillo F.J.; Imported Pathology Group of the SEIMC. 2023. Screening for strongyloidiasis in Spain in the context of the SARS-CoV-2 pandemic: results of a survey on diagnosis and treatment. *Enfermedades Infecciosas y Microbiología Clínica (Engl Ed)* 41(6): 329–334. doi:10.1016/j.eimce.2022.08.006
- [98] Miret R., Acosta-Rullan J.M., Toll A., Honeycutt G., Malhi M., Zorrilla C.A., Diaz R., Danckers M., Zapata D. 2025. The unwelcome guest: *Strongyloides stercoralis* hyperinfection in a patient with steroid-dependent asthma-COPD overlap syndrome (ACOS) – a case report and review of literature. *Case Reports in Pulmonology*: 3204304. doi:10.1155/crpu/3204304
- [99] Schär F., Trostdorf U., Giardina F., Khieu V., Muth S., Marti H., Vounatsou P., Odermatt P. 2013. *Strongyloides stercoralis*: global distribution and risk factors. *PLoS Neglected Tropical Diseases* 7(7): e2288. doi:10.1371/journal.pntd.0002288
- [100] Gelaye W., Williams N.A., Kepha S., Junior A.M., Fleitas P.E., Marti-Soler H., Damtie D., Menkir S., Krolewiecki A.J., van Lieshout L., Enbiale W. 2021. Stopping transmission of intestinal parasites (STOP) project consortium. Performance evaluation of Baermann techniques: the quest for developing a microscopy reference standard for the diagnosis of *Strongyloides stercoralis*. *PLoS Neglected Tropical Diseases* 15(2): e0009076. doi:10.1371/journal.pntd.0009076
- [101] Albermann S., Vischer A., Vu X.L., Horat A., Grimm F., Nickel B., Gottstein B., Hirzel C., Oberli A. 2025. Serodiagnosis of strongyloidiasis in a low-endemic setting – a two-tiered test approach. *Travel Medicine and Infectious Disease* 67: 102890. doi:10.1016/j.tmaid.2025.102890
- [102] Arifin N., Hanafiah K.M., Ahmad H., Noordin R. 2019. Serodiagnosis and early detection of *Strongyloides stercoralis* infection. *Journal of Microbiology, Immunology and Infection* 52(3): 371–378. doi:10.1016/j.jmii.2018.10.001
- [103] Kadkhoda K., Gibson Jr., B. 2020. Evaluation of a new *Strongyloides* ELISA IgG test kit. *Clinical*

- Laboratory* 66(12):  
doi:10.7754/Clin.Lab.2020.200319
- [104] Hailu T., Nibret E., Amor A., Munshea A., Anegagrie M. 2020. Efficacy of single dose ivermectin against *Strongyloides stercoralis* infection among primary school children in Amhara National Regional State. *Infectious Diseases (Auckl)* 13: 1178633720932544.  
doi:10.1177/1178633720932544
- [105] Buonfrate D., Salas-Coronas J., Muñoz J., Maruri B.T., Rodari P., Castelli F., Zammarchi L., Bianchi L., Gobbi F., Cabezas-Fernández T., Requena-Mendez A., Godbole G., Silva R., Romero M., Chiodini P.L., Bisoffi Z. 2019. Multiple-dose versus single-dose ivermectin for *Strongyloides stercoralis* infection (Strong Treat 1 to 4): a multicentre, open-label, phase 3, randomised controlled superiority trial. *The Lancet Infectious Diseases* 19(11): 1181–1190.  
doi:10.1016/S1473-3099(19)30289-0

Received 22 September 2025

Accepted 15 December 2025